

Surgery of the ear and pinna

Otto I. Lanz, DVM*, Brett C. Wood, MS, DVM

*Department of Small Animal Clinical Sciences, Virginia-Maryland Regional College
of Veterinary Medicine, Phase II Duck Pond Drive Road, Blacksburg, VA 24061, USA*

Anatomy of the ear

The ear can be divided into three anatomic regions: the external ear, which consists of the auricle or pinna and the external auditory meatus; the middle ear, which is formed by the tympanic cavity and connects to the pharynx by way of the Eustachian tube; and the inner ear, which consists of a membranous and bony labyrinth that functions for hearing and balance. The middle ear and the external ear are separated by the tympanic membrane, and the auditory meatus marks the opening of the horizontal canal into the middle ear. The auditory ossicles connect the tympanic membrane to the inner ear.

The external ear varies in size and shape according to the breed of dog. The appearance of the canine pinna is dependent on the auricular cartilage. The auricular cartilage is elastic and thin at the apex and then rolls into a semitube at the base. The pinna is covered with skin on both sides, which is closely attached to the perichondrium of the auricular cartilage. The pinna functions to capture, focus, and localize sound. The free edge of the auricular cartilage is called the helix. It is divided into medial and lateral parts that unite at the apex of the ear. The antihelix is a low horizontal ridge with a prominent tubercle located on the medial wall of the entrance into the ear canal (Fig. 1). Opposite the anthelix and forming the lateral wall of the entrance to the external ear canal is a dense cartilage plate called the tragus. The antitragus is a thin cartilaginous plate caudal to the tragus. The caudal auricular artery and vein branch and form the lateral, intermediate, and medial vascular rami that course along the convex surface of the pinna. The lateral, intermediate, and medial rami directly penetrate the scapha to supply the convex surface of the pinna. Survival of the pinna is directly dependent on maintaining the integrity of these rami.

* Corresponding author.

E-mail address: olanz@vt.edu (O.I. Lanz).

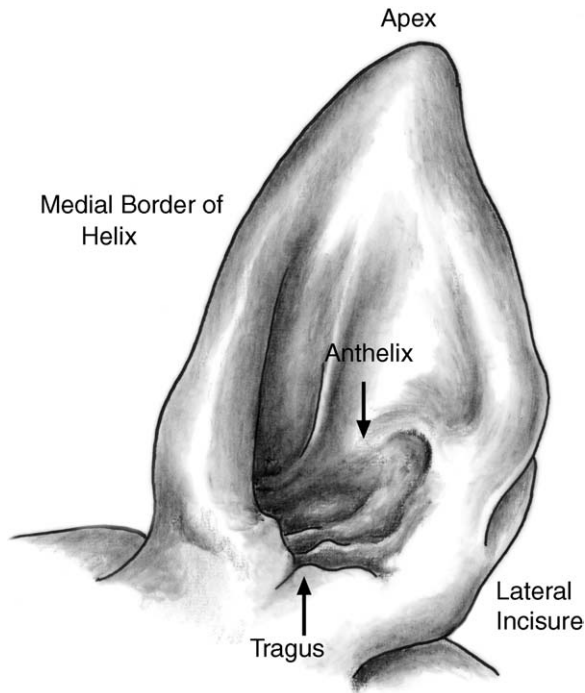


Fig. 1. Landmarks of the external ear.

The external ear canal is composed of cartilaginous and osseous tissue and extends from the external acoustic opening to the tympanic membrane. The external acoustic opening is positioned dorsolaterally in most animals. Starting at the external acoustic opening, the vertical part of the ear canal is directed ventrally, medially, and rostrally. The canal turns medially forming the horizontal canal, which attaches to the tympanic membrane. The first part of the canal is formed by the rolled auricular cartilage and then is continued medially by the annular cartilage. The annular cartilage telescopes into the auricular cartilage and is attached to the auricular cartilage and to the temporal bone by ligamentous tissue. Secreting sebaceous glands are prominent and numerous in the peripheral parts of the external ear canal but are much smaller in the lining of the osseous canal. Apocrine glands are present in the deeper layer below the sebaceous glands in the peripheral part of the ear but are sparse in the deeper parts of the canal. The normal ear secretion, cerumen, is a product of both gland types.

The tympanic membrane separates the external ear from the middle ear. It is a thin semitransparent sheet that is thin centrally and becomes thicker toward the periphery. The membrane is divided into two parts: the pars flaccida and the pars tensa. The pars flaccida is a small triangular portion that lies between the lateral process of the malleus and the margin of the

tympanic incisure. The remainder of the membrane is composed of the pars tensa.

The tympanic cavity in the dog is composed of a small dorsal epitympanic recess and a large ventral tympanic bulla. The tympanum is filled with air, and a thin layer of columnar ciliated epithelium lines the wall, which is continuous with the nasopharynx through the Eustachian tube. A thin layer of simple squamous epithelium lines the ventral portion of the tympanic cavity, auditory ossicles, tympanic membrane, and membranes over the cochlear and vestibular foramina. The three ossicles bridge the narrow cavity of the tympanum from the tympanic membrane to the vestibular foramen.

The malleus, the largest and outermost of the three ossicles, attaches laterally to the tympanic membrane. The incus lies caudal to the malleus in the epitympanic membrane. The stapes is the innermost ossicle and lies in a horizontal plane with the base facing medially. The stapes is connected to the vestibular foramen and acts as the final chain in transmitting impulses from the external ear to the inner ear.

The inner ear consists of three parts: the cochlea, vestibule, and semicircular canals, which together make up the osseous labyrinth. The osseous labyrinth is lined with membranes that form the membranous labyrinth, which is a closed-duct system filled with endolymph. The cochlea of the inner ear is involved with hearing, whereas the vestibule and semicircular canals are important for maintaining equilibrium. The membranous labyrinth serves as the sensory end organ for the vestibulocochlear nerve and the vestibular mechanism.

The feline tympanic cavity is divided into two compartments, a small dorsolateral compartment and a larger ventromedial compartment, which are separated by a thin bony septum. Most of the lateral portion of the dorsolateral compartment is formed by the tympanic membrane. The compartments communicate through a narrow fissure located in the caudomedial aspect of the bony septum. The sympathetic nerves form a plexus on the promontory, which is located near the fissure.

Aural hematomas

Aural hematoma is the most common injury to the pinna (Fig. 2) [1–6]. The hematoma is a direct result of self-trauma, such as scratching the pinna or continued head shaking. The auricular cartilage is nourished through branches of the caudal auricular artery that penetrate the auricular cartilage through numerous foramina. The concave or inner surface of the pinna is firmly attached to the skin. After trauma to the pinna, hemorrhage occurs and accumulates between the cartilage and the skin. Hemorrhage from the cartilage continues as a result of persistent ear scratching or head shaking, which further dissects the skin away from the auricular cartilage, forming a hematoma. Left unabated, the hematoma matures, leaving a sanguineous

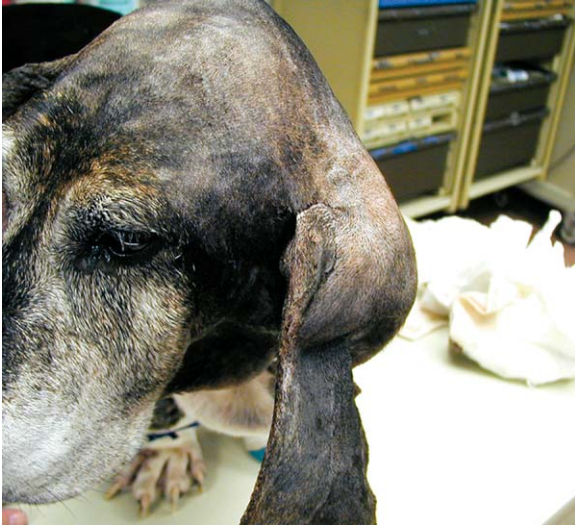

Fig. 2. An example of a dog with an aural hematoma secondary to otitis externa.

seroma. Over time, granulation tissue forms on the wall of the cartilage and eventually leads to contraction and fibrosis, causing deformity and thickening of the pinna.

Aural hematomas occur in dogs and cats. The exact cause is unknown at the present time, but the most plausible cause is fracture of the auricular cartilage secondary to head shaking or vigorous ear scratching. Autoimmunity was suggested as a cause in some cases; however, a recent study failed to support a correlation between autoimmune pathogenesis and aural hematoma in the dog [4]. This study did suggest that an early immunologic event might cause erosion of the cartilage commonly seen in dogs with aural hematomas [4]. In many cases involving aural hematomas, there is concurrent otitis externa. In cats with aural hematomas, ear mites and subsequent otitis externa may be evident. A thorough otoscopic examination of the ear is warranted in all animals afflicted with aural hematomas, and the underlying ear disease should be treated appropriately in concurrence with surgical drainage.

Therapeutic objectives for aural hematomas consist of (1) identifying and properly treating the source of the head shaking or ear scratching, (2) providing proper drainage, and (3) maintaining proper apposition between the skin and cartilage of the ear [1]. If these objectives are met, recurrence is unlikely. There are numerous techniques described for the surgical treatment of aural hematomas. Drainage of the hematoma should be done as soon as possible to prevent deformity of the pinna secondary to fibrosis and contraction of the hematoma. The simplest technique for allowing drainage of the hematoma is through needle aspiration. The concave surface

of the ear should be clipped and aseptically prepared before performing needle aspiration. Injecting glucocorticoids after aspiration of the hematoma is discouraged, because this further separates the auricular cartilage from the skin and delays healing [1,2]. Oral prednisone (anti-inflammatory doses) can be administered to decrease the amount of head shaking and ear scratching. Needle aspiration should be performed daily to prevent early recurrence of the hematoma. If the hematoma is chronic, needle aspiration is not effective. Drains and cannulas are also used as a means to provide continued long-term drainage until healing can occur and should only be used if minimal fibrin is present within the hematoma. A teat cannula is placed aseptically through a small stab incision at the apex of the ear in the dependent portion of the hematoma. Another option for drainage consists of a through-and-through drain. After aseptic preparation of the pinna, a stab incision is made at the proximal and distal portion of the hematoma. The hematoma is expressed and flushed with saline through the stab incisions. A Penrose drain is fed through the cavity exiting each stab incision and fastened with nonabsorbable suture at each portal, making sure not to occlude the drain. The drain is removed at the end of 2 weeks.

Closed-suction drains constructed from butterfly catheters are reported as an effective means of draining hematomas [1]. The injector port is removed from the butterfly catheter, and the distal portion of the catheter is fenestrated. A small stab incision is made at the proximal end of the hematoma, and the fenestrated portion of the catheter is inserted into the cavity of the hematoma. To ensure an airtight seal, a purse-string suture is placed around the stab incision and the needle portion of the butterfly catheter is inserted into a vacuum blood tube to create a constant vacuum (Fig. 3). The ear is bandaged over the head along with the vacuum tube. The vacuum tube is replaced based on the amount of drainage. This technique is not recommended if the animal is extremely active, because this is likely to cause premature catheter removal or separation of the needle from the vacuum tube.

Cases involving chronic hematomas are best treated with incisional drainage. After the incision, through-and-through mattress sutures are placed to obliterate dead space between the auricular pinna and skin. The sutures should be placed parallel to the vessels located on the convex surface of the pinna, making sure to avoid penetrating the vessels with the needle. The sutures should be tightened only enough to allow apposition of the skin and cartilage. Sterile sponges can be placed on the convex surface of the ear and incorporated with the mattress sutures, which helps to prevent overtightening of the sutures. Sutures are left in place for 10 to 14 days, and the ear is bandaged over the dorsum of the head. Creating multiple circular holes on the concave surface of the ear with a 4-mm dermal biopsy punch is an effective way of allowing auricular hematomas to drain. The circular defects close slowly by second intention healing. The circular holes should be placed approximately 1 cm apart. The ear is bandaged over the

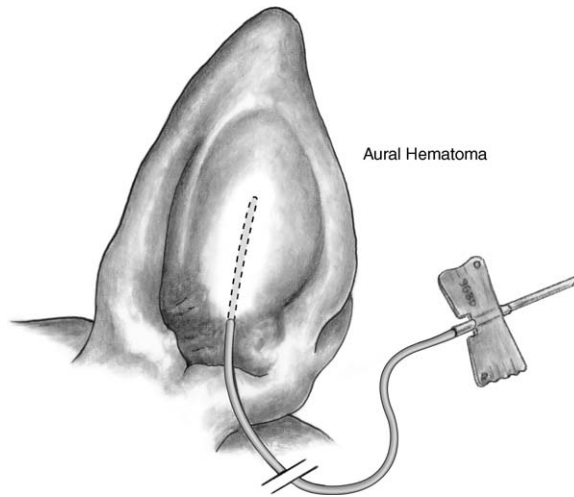


Fig. 3. Closed-suction drains constructed from butterfly catheters can be used as an effective means of draining aural hematomas.

dorsum of the head until the circular defects heal via second intention. A similar technique has recently been reported in which a carbon dioxide laser is used to create small defects over the hematoma. The ear is bandaged over the dorsum of the head for a few days until the openings heal by second intention. Cosmetic results after carbon dioxide laser surgery for aural hematomas are encouraging. Cyanoacrylates have also been used as a technique for repair of aural hematomas. After drainage of the hematoma, cyanoacrylate is injected in the ear between the pinna and skin on the concave surface of the ear [3]. The authors do not recommend this technique, because cyanoacrylates are associated with intense granuloma formation.

The use of bandages is important when treating cases of aural hematoma. The bandage protects the ear from further iatrogenic damage and keeps the cartilage and skin apposed. The bandage also protects the incision from contamination and provides a means to secure cannulas, draining tubes, or vacuum tubes. Reportedly, it is more comfortable to bandage a dog's ear over the neck than over the dorsum of the head. The exact duration of bandaging is left up to the discretion of the surgeon, but bandages should be left on until there is minimal drainage or adequate granulation tissue.

Ear lacerations

Lacerations of the ear are most commonly associated with dog bites. These wounds are classified according to the depth of the laceration. They may only affect the skin on one surface of the pinna, the skin on one surface of the pinna and cartilage, or both skin surfaces of the pinna and cartilage [7]. Small lacerations involving only one skin surface may be left to heal by

second intention after the wound has been cleaned, the edges debrided, and the wound properly assessed. Primary closure of ear lacerations should be performed when two- or three-sided flaps are formed. If these lacerations are left open to heal by second intention, the result is usually a malaligned or deformed ear depending on the initial severity of the laceration. Lacerations located on the periphery of the ear may widen over time if left untreated as a result of contracture and epithelialization. If these wounds are closed primarily, cupping or folding of the ear results because of the contraction of the wound. Cosmetic results can be obtained with partial amputation of the pinna if the wound is small and peripherally located. The skin edges are rolled together using a simple continuous pattern with 4-0 absorbable suture. The ear should be bandaged until the wound properly heals.

Larger wounds can be repaired by use of a single pedicle flap [7]. The wound is first properly debrided, removing as little tissue as possible, and bandaged for 7 days to provide a healthy surface for the flap. The donor sight for the flap is constructed on the lateral surface of the neck or muzzle depending on the conformation of the dog. The edges of the wound are carefully debrided, and the ear is placed over the donor site to create a pattern for the flap. The pattern is incised, and extending incisions are made in the cranial and caudal portions of the flap extending ventrally for a few millimeters. The lateral surface of the pinna (convex surface) is sutured to the flap. The ear is bandaged in place for 2 weeks, and the bandage is changed as needed. After 2 weeks, the flap is incised from the donor site to complete closure of the lateral (convex) surface of the ear. The medial surface of the ear can be reconstructed by several means. The most consistent survival results from forming a second flap using the skin on top of the head as the donor sight. The medial surface of the ear is sutured to the donor sight on top of the head for 2 additional weeks, with the bandage being changed accordingly. After 2 weeks, the flap is removed and the distal portion of the flap is sutured to the distal portion of the previous flap to complete the reconstructive procedure.

Lateral wall resection

Indications for performing a lateral ear canal resection include biopsy or removal of benign polyps of the ear and for cases of otitis externa that have not responded to proper medical management. For a lateral wall resection to be successful, it is imperative that hyperplastic disease is not present in the ear canal. A lateral ear canal resection provides ventilation, reducing the moisture, humidity, and temperature of the ear canal providing favorable conditions for bacterial growth (Fig. 4). The lateral wall resection does not cure the animal of its underlying disease but improves the microenvironment of the ear. One retrospective study evaluated 60 dogs that underwent lateral wall resection. The study found that the surgical outcome was acceptable in 45% of the cases and unacceptable in 55% of the cases [8]. The only factor

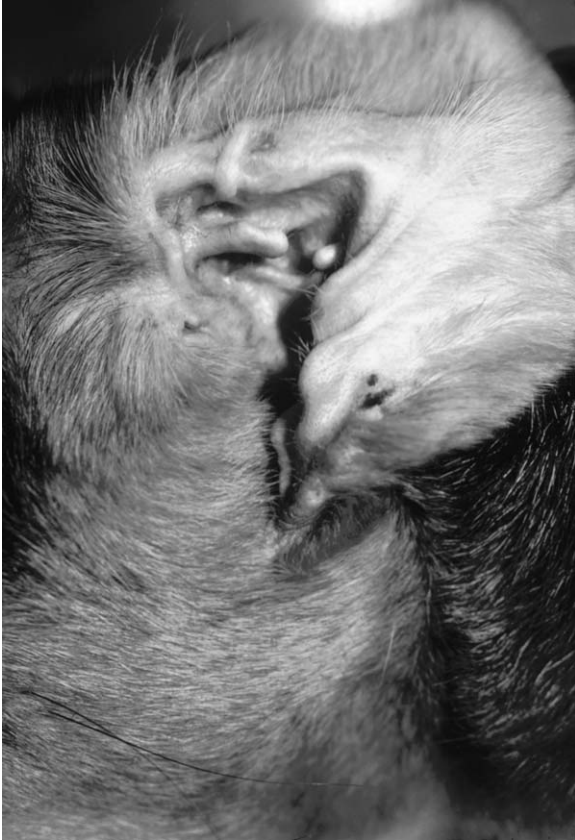

Fig. 4. An example of a lateral wall resection 6 months after surgery.

that correlated with the outcome was breed. Lateral wall resection failed in 86.5% of the Cocker Spaniels. When the surgical outcome in breeds other than Cocker Spaniels was evaluated, 63% were acceptable and 37% were unacceptable [8]. Interestingly, Sharpeis were found to have an ear canal of smaller diameter compared with that of other breeds and to have a tendency to have better outcomes. A lateral wall resection is successful in cases of otitis externa when it is performed properly and medical care of the ear is continued. It is important to consider resection of the lateral wall of the ear as a prophylactic procedure instead of a salvage procedure.

In a lateral wall resection, the skin overlying the canal is removed by making incisions along the rostral and caudal borders of the vertical ear canal extending ventral to the horizontal canal. The dorsal and ventral ends of the skin incisions are joined, and the skin is removed. Cartilage scissors are then used to incise along the rostral and caudal border of the vertical canal to the level of the annular cartilage. It is important to remove at least 50% of the circumference of the vertical ear canal [9]. The lateral portion of

the vertical ear canal is then reflected ventrally. The distal third of the vertical ear canal is used to create a drain board. The drain board is sutured to the ventral skin incision with nonabsorbable suture on a cutting needle. Sutures are best placed through the cartilage first and then through the skin. It is important to pay particular attention when suturing the rostral and caudal portions of the vertical canal at the hinge point of the flap to ensure maximum opening of the horizontal canal (Figs. 5 and 6). The closure is continued dorsally, apposing the rostral and caudal portions of the vertical ear canal to the skin.

Postoperative management consists of continued medical management of the otitis externa along with temporary bandaging of the pinna on the head of the dog. Skin sutures are removed in 10 to 14 days. An Elizabethan collar should be placed on the animal to prevent self-mutilation of the surgical sight. Postoperative analgesics should be provided as well. Surgical complications after a lateral wall resection are usually related to failure to recognize and treat the underlying cause of otitis externa, failure to provide adequate drainage of the horizontal canal, or failure to perform the procedure correctly. Incisional dehiscence has also been reported as a common postoperative complication in animals undergoing lateral wall

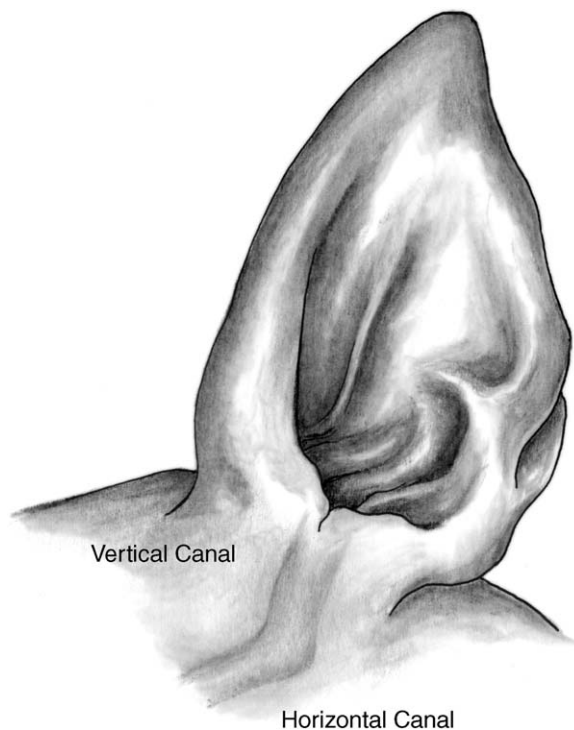


Fig. 5. It is important to remove at least 50% of the circumference of the vertical ear canal.

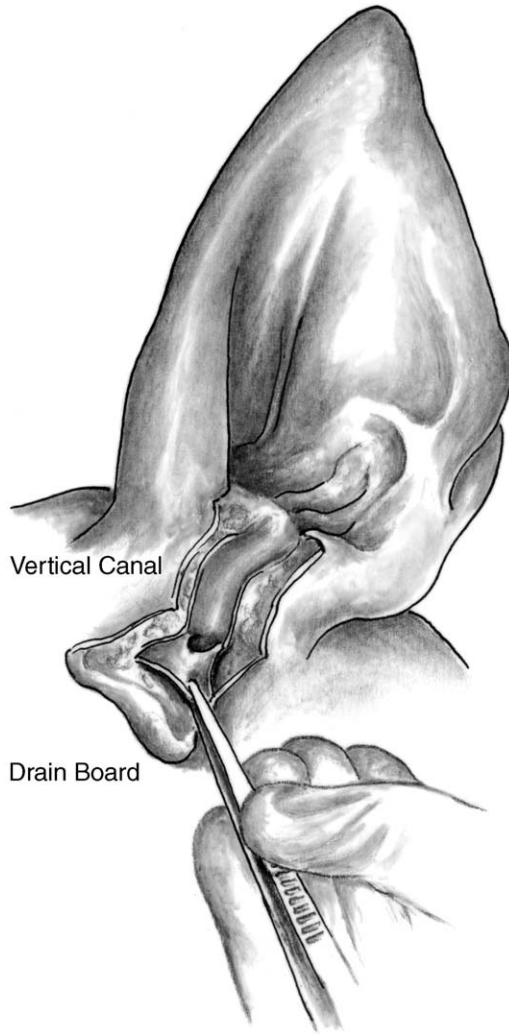


Fig. 6. Particular attention must be paid when suturing the rostral and caudal portions of the vertical canal at the hinge point of the flap to ensure maximum opening of the horizontal canal.

resection. If dehiscence of the wound occurs, the wound is best left open to heal by second intention with proper wound management.

Vertical canal ablation

Vertical ear canal ablations are seldom performed. They are performed when the vertical ear canal is diseased but the horizontal canal is free from disease. Indications for performing a vertical ear canal ablation include hyperplastic otitis externa, trauma, neoplastic disease, and polyps restricted

to the vertical ear canal. The advantages of the procedure include preservation of hearing, drainage and ventilation of the horizontal canal, and complete removal of diseased tissue. It is important before performing a vertical ear canal ablation to make sure that the disease process does not involve the horizontal canal. CT or MRI should be performed to ensure that the horizontal canal is not involved.

The surgical procedure is initiated by creating a triangular incision around the opening of the ear and the vertical ear canal, with the base of the triangle located dorsally. The tissue and muscles surrounding the vertical ear canal are carefully dissected free. The dissection is continued in a circular fashion until the annular and auricular cartilages are exposed. The vertical ear canal is then transected and submitted for histopathology. The opening of the horizontal canal is sutured into the ventral end of the initial V-shaped incision. The remainder of the wound is closed in a T-shaped form. An alternative way to suture the horizontal canal is to create a ventral drain board similar to a lateral wall resection. Using the lateral wall of the vertical canal creates the drain board ventrally. This modification decreases the chance of horizontal canal stenosis (Fig. 7) [9].

Postoperative care is similar to that for a lateral ear canal resection. It is important that the underlying disease be treated appropriately. If needed, the hair surrounding the horizontal canal can be clipped often to allow for proper drainage.

Total ear canal ablation/lateral bulla osteotomy

Total ear canal ablation (TECA) is considered a salvage procedure where the vertical and horizontal ear canal cartilages and epithelial lining are

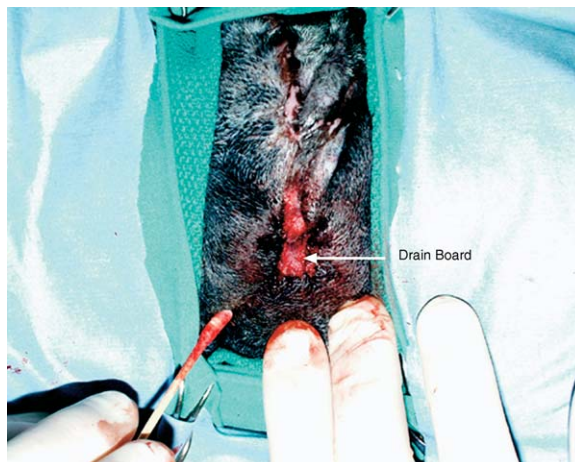


Fig. 7. Using the lateral wall of the vertical canal creates the drain board ventrally. This modification decreases the chance of horizontal canal stenosis.

removed surgically [10]. This procedure is most commonly indicated for the removal of infectious ear canal tissues formed as a result of chronic otitis externa (Fig. 8) [11,12]. Irreversible ear canal disease is present when one or more of the following clinical signs are observed: hyperplastic epithelium occluding the horizontal or vertical ear canals or the external acoustic meatus, collapse/stenosis of the horizontal ear canal caused by infection, or evidence of calcified periauricular tissues [13,14]. Aural trauma, ear canal neoplasia, and congenital malformations, which obstruct proper ear canal drainage, are also indications for surgical intervention [15–20]. Initially, treatment for end-stage ear canal disease consisted of ablation of the ear canal and epithelium alone, and complication rates as high as 82% were noted [10,21]. In a significant number of animals with severe chronic otitis externa, there is also evidence of otitis media. In these patients, the auditory tube alone is thought to provide inadequate drainage of the tympanic cavity, and recurrent infections and draining tracts are believed to be the long-term sequelae [11–14]. The complication rate was decreased considerably [11,12,14,22] when the procedure was combined with surgical curettage of the tympanic bulla lining and a lateral bulla osteotomy (LBO). One report used a ventral bulla osteotomy in conjunction with TECA, but there was a 31% rate of permanent facial nerve damage and no improvement seen in terms of decreased complications or recurrence of disease [23].

In the preoperative period, there are several factors to consider. One of the most important considerations is the comprehensive preoperative patient examination to determine the extent of disease present and any early complications that may exist. The other important consideration is to ensure that the client has a firm understanding of not only the procedure to

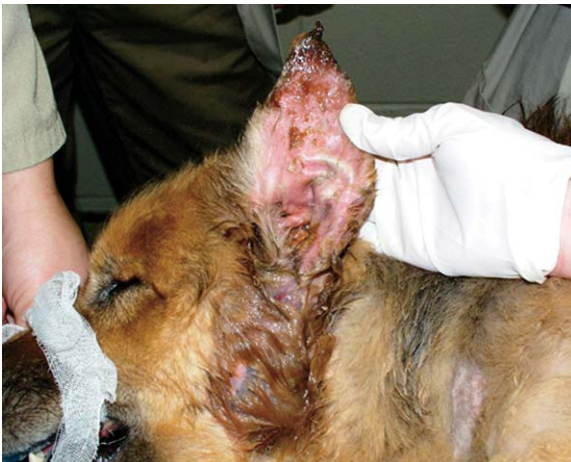

Fig. 8. Total ear canal ablations are most commonly performed to remove infectious ear canal tissue formed as a result of chronic otitis externa.

be performed but the patient's current status and the possible complications associated with each procedure. The evaluation begins with a complete physical examination. Clinical evidence of otitis externa includes evidence of thickened or calcified ear canal tissue, pain on palpation of the region, purulent discharge and an odor from the ear canal, and hyperplastic tissue surrounding the external acoustic meatus. If there is evidence of a bloody discharge or the clinical signs are unilateral and have progressed in a short time, neoplasia should be considered before chronic otitis externa [13,14,24]. Because chronic ear canal problems occur in conjunction with or as a direct result of concurrent dermatologic problems, a complete dermatology examination should be performed. Concurrent dermatologic disease is seen in 64% to 80% of patients presented for TECA/LBO and includes primary keratinization disorders in Cocker Spaniels, seborrhea, atopy, food allergies, pyoderma, flea infestation, and hypothyroidism [11,22]. In addition, there are breed variations in the histologic features noted in the ear canal pathology associated with chronic otitis externa, which could be a result of the primary (dermatologic) causes of the otitis externa [25]. Proper diagnostic evaluation and owner education are important when other dermatologic disease is present, because TECA/LBO only addresses the clinical signs of the otitis externa/media but does not address the underlying pathology present, which remains a source of concern for the patient and client in many cases.

A complete neurologic examination should also be performed to determine if there is any facial nerve or peripheral vestibular involvement. Preoperative facial neuropathy is important to determine because it occurs in a significant number of dogs [13,24,26]. Significant neurologic deficits can also be noted with extension of chronic otitis externa/media, a neoplastic process that leads to problems with peripheral vestibular syndrome, or with meningoencephalitis secondary to bacterial otitis media/interna [27,28]. In addition to any neurologic deficits, the owner should be questioned as to the amount of hearing he or she believes the patient has; if there is any question, more quantitative tests should be performed. Hearing ability can be more objectively determined using a brain stem auditory evoked response (BAER). BAER testing can be performed in relation to either air-conducted or bone-conducted stimuli [29]. In most cases, there is a good association between the owner's subjective assessment and the BAER testing, and there is not a significant effect seen with performance of TECA/LBO in most cases [30].

Otoscopy of the ear canals can be attempted in patients with severe otitis externa/media while they are awake and sedated. In most cases, it is much more efficient and humane to perform this procedure under general anesthesia. Inspection of the tympanic membrane is important; if it is absent, otitis media can be assumed, and if it is present, it can be examined for signs of material within the tympanic cavity. If the tympanic membrane is intact, a myringotomy can be performed if preoperative bacterial cultures

are desired or samples can be collected directly from the bulla at the time of surgery.

Radiographic evaluation of the external, middle, and internal ear is warranted to determine if there is evidence of otitis media or, in instances where neoplasia is a concern, to look for evidence of tympanic bulla lysis or proliferation. Radiographic examination of the external ear canal, tympanic membrane, and tympanic bulla involves the use of plain film radiography, CT, or MRI. Although plain film radiography is used commonly to evaluate patients, assessment of this procedure's ability for demonstrating changes in dogs with otitis media is not considered highly sensitive [31]. As a result of the fact that the horizontal ear canal and tympanic membrane cannot be visualized in a certain percentage of cases with otitis externa, positive-contrast ear canalography has also been used to determine if there is evidence of either a ruptured tympanic membrane or stenosis of the horizontal ear canal [32,33]. In dogs with ear disease, canalography may be more sensitive for otitis media than either otoscopic examination or plain film radiography [33]. In a comparison between CT evaluation and plain film radiographs for evaluation of otitis media, CT evaluation (83%) was found to be slightly more sensitive than plain film radiography (67%), but the specificity was slightly lower (89% versus 100%) (Figs 9 and 10). In cases where vestibular signs are present and it is not possible to differentiate between a central and peripheral vestibular syndrome, MRI has been used to evaluate possible caudal fossa parenchyma brain lesions and middle ear pathology [34]. In most cases, however, if the index of suspicion for otitis media is high based on chronic otitis externa or associated neurologic deficits, surgical exploration of the middle ear is indicated [31].

There are many variations of the basic surgical technique for performing TECA/LBO. The patient's entire pinna and lateral aspect of the head are clipped and surgically prepared for surgery. The ear canal should be repeatedly lavaged with an antiseptic solution to remove as much debris and contamination as possible; however, this procedure is still considered a clean-contaminated to contaminated surgical procedure in most instances [13,14]. Prophylactic intravenous antibiotic therapy should be initiated before skin incision. Ninety percent of isolates are susceptible to amoxicillin-clavulanate, ciprofloxacin, or ticarcillin antibiotics [35]. Positioning of the animal should be in lateral recumbency with the head resting in a slight dorsal oblique direction so as to optimize exposure to the regions of the ear canal and tympanic bulla during the procedure. An elliptical incision is made around the opening of the ear canal and includes all hypertrophied ear canal tissue (Fig. 11). Using a pair of Mayo or Martin cartilage scissors, a division between the affected and unaffected auricular cartilage is made by sharp dissection. Using a combination of blunt and sharp dissection, the vertical auricular canal cartilage is dissected from the surrounding tissue. Exposure of the surgical site is facilitated by an assistant who can retract the ear canal while applying tension in the opposite direction from the dissection using a pair of Allis

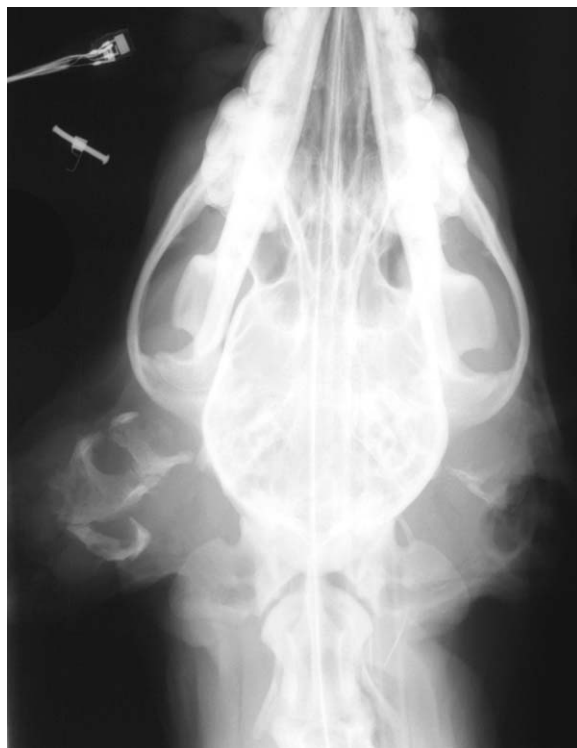

Fig. 9. Calcification of the external ear canals in a dog with chronic otitis externa.

tissue forceps. The use of a pair of small Weitlaner or Gelpi retractors can also assist the surgical exposure. The authors prefer to use a self-retaining circular ring retractor (Lone Star Retractor; Lone Star Medical Products, Houston, Texas), which uses multiple elastic stays to provide even and adjustable tension on the surgical field. Dissection can be assisted with the use of electrocautery or a carbon dioxide laser to decrease the amount of hemorrhage from the inflamed periauricular tissue. Damage to the branches of the great auricular vasculature medial to the ear canal should be avoided because it can lead to development of vascular necrosis of the pinna [24]. The dorsal attachments of the auricular muscles and the perichondrium of the ear canal are also dissected free. The remainder of the vertical and horizontal canal is dissected free from the surrounding tissue until the annular cartilage attachment to the external auditory meatus is reached. At the junction of the auricular and annular cartilage, dissection should be cautious in the ventral caudal region, because the facial nerve courses through this region and should be identified and avoided. The ear canal is removed (Fig. 12) by incising the proximal annular cartilage attachments by using a number 15 blade directed in a caudal-to-cranial direction so as to avoid trauma to the

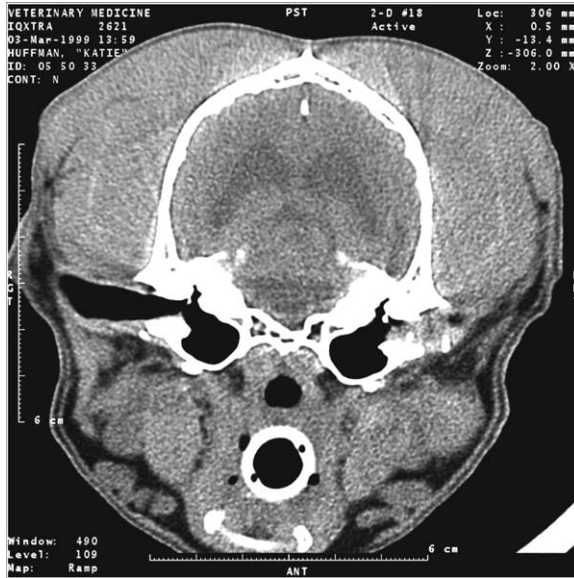

Fig. 10. CT scan of a dog with stenosis of the left ear canal.

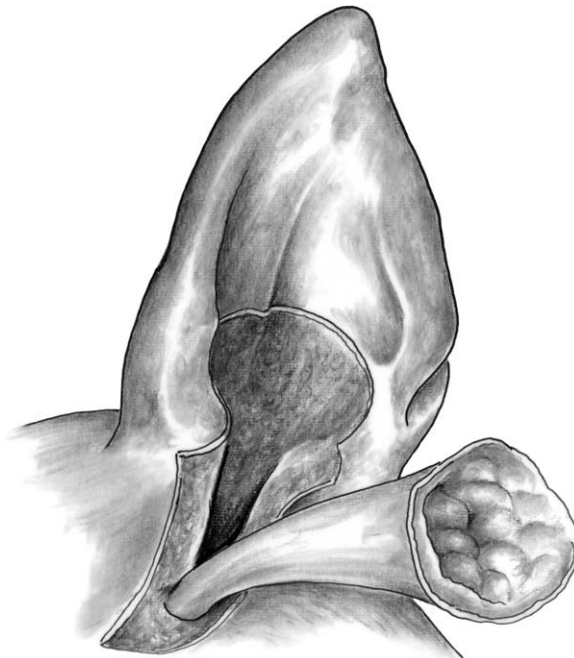

Fig. 11. An elliptical incision is made around the opening of the ear canal and includes all hypertrophied ear canal tissue.

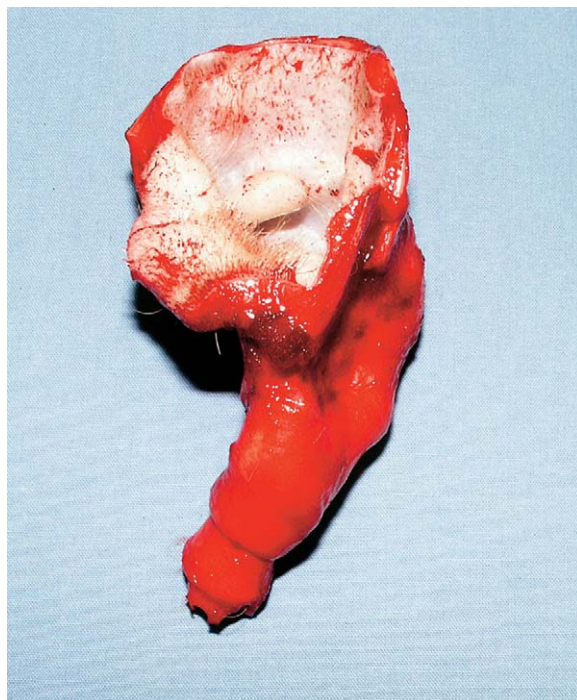


Fig. 12. Complete removal of the vertical and horizontal canal after total ear canal ablation and lateral bulla osteotomy.

facial nerve as it exits the stylomastoid foramen. If there is excessive mineralization of the cartilage, a small osteotome can be used for incising the connection or removal of the proximal canal and epithelial remnants can be done with a bone rongeur. Bacterial cultures should be obtained for both tympanic bulla, because it is common to have multiple different bacterial species isolated from each ear [35,36]. At this point, the soft tissue covering the tympanic bulla is elevated to expose the lateral and ventral portions of the bulla. Care should be taken not to damage the retroglennoid vein, which lies ventromedial to the bulla. The lateral bulla osteotomy can be performed with bone curettes, rongeurs (Lemperts, Ruskin, or Love-Kerrison rongeurs), or a high-speed air-driven burr (Surgairtome; 3M Company, Santa Barbara, California) (Fig. 13). Removal of the auditory ossicles is recommended by some surgeons because of the belief that osteomyelitis of the ossicles is most likely present with concurrent otitis media, although removal has not been shown to decrease the incidence of recurrent fistulation or overall occurrence of deafness and is not routinely performed [12,24]. Once the bulla osteotomy is performed, curettage of the bulla is performed using bone curettes to remove all residual debris and epithelial lining from the tympanic bulla. The dorsal (epitympanic recess and auditory ossicles) and dorsomedial

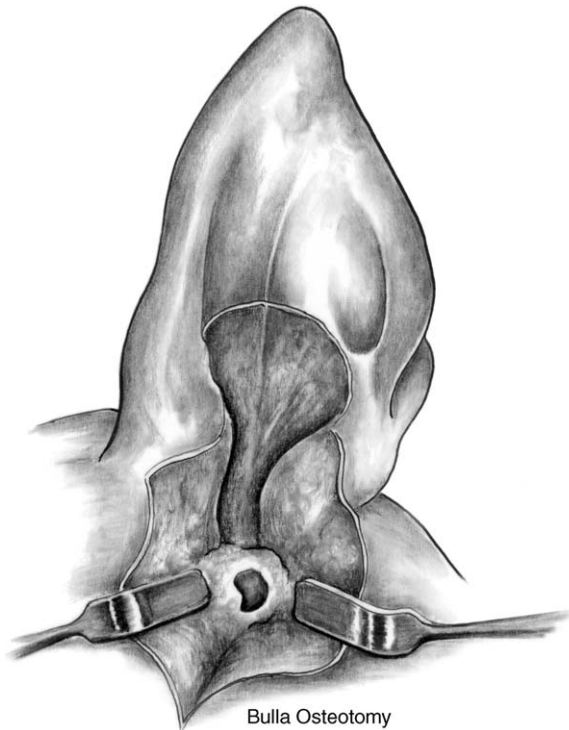


Fig. 13. The lateral bulla osteotomy can be performed with bone curettes, rongeurs, or a high-speed air-driven burr.

(promontory and inner ear structures) portions of the bulla are avoided so as to decrease the chance of postoperative iatrogenic vestibular deficits [24]. Removal of the secretory lining of the tympanic bulla is essential for a successful surgical outcome, because chronic abscessation and fistulation are likely to occur if remnants remain. The bulla should be lavaged with a physiologic saline solution to remove residual contamination, remnants of epithelial lining, and bone from the tympanic bulla. Placement of a drain is according to the surgeon's preference, but primary closure of the wound without wound drainage is also considered an acceptable alternative [37]. Closure of the TECA/LBO consists of a simple interrupted suture pattern using an absorbable monofilament suture material to decrease the amount of dead space. Care must be taken with deeper suture bites not to engage the facial nerve. A continuous or interrupted intradermal suture pattern using an absorbable monofilament suture material can then be placed.

Postoperative care consists primarily of analgesia, bandaging, and continued antibiotic therapy. Routine analgesia for TECA/LBO is recommended because of the amount of discomfort observed in animals having this procedure performed. Analgesia protocols consist of preoperative, operative,

and postoperative interventions to decrease the pain and anxiety associated with the procedure. In the preoperative period, application of a transdermal fentanyl patch (Duragesic; Janssen, Titusville, New Jersey) 12 to 24 hours before the procedure ensures that the serum levels of the medication are within the therapeutic range and efficacious for 48 to 72 hours. If a transdermal patch is applied, however, it must be protected during the procedure from heat sources (eg, warm-water blanket) that could increase intradermal absorption and lead to possible toxicity issues. Local nerve blockade before surgery is another technique used, but in one study, it was not found to decrease observed and metabolic markers of postoperative pain and anxiety; however, subjectively, these dogs were easier to manage anesthetically during the surgical procedure [38]. Intraoperative analgesia can be attempted using a single splash block of bupivacaine, or a device can be placed that allows for continuous local infusion of bupivacaine in the postoperative period. Neither single nor continuous nerve blockade was found to be clinically useful for decreasing observed or metabolic markers of pain in the postoperative period [38,39]. Administration of injectable opiate medications by either intermittent or continuous rate infusion is recommended for the first 24 to 48 hours after surgery. After this time, administration of oral analgesics, either nonsteroidal anti-inflammatory drugs (NSAIDs) or opiate/NSAID combinations, is recommended for an additional 5 to 7 days after surgery.

The ears are placed on top of the head, and a nonadherent primary layer of bandage material is placed on the surgical wound. A loose bandage is then placed around the head (and drains if placed) and is maintained for 24 to 36 hours (if no drains were placed) or until the drains are removed. During the immediate postoperative period, observation of these animals must be vigilant to ensure that there is no evidence of ventilatory compromise as a result of pharyngeal swelling and compression caused by the bandaging material. Elizabethan collars are recommended until suture removal in all cases to decrease the chance of damage to the wound closure either through scratching of the wound with the paws or swinging of the ears causing possible hematoma formation. If there is excessive drainage, swelling, or bruising of the region, applying a warm compress (two to three times daily for 5–10 minutes) is recommended. Routine use of eye lubricants is recommended in the postoperative period because of the effect of general anesthesia on tear production and any decreased ability to blink as a result of either temporary or permanent nerve damage [40]. Antibiotic therapy is dependent on culture and sensitivity results and is continued for an additional 3 to 4 weeks after surgery (6–8 weeks if severe bulla osteomyelitis is identified). There have been several reports examining the results of microbial culture and sensitivity results in dogs with otitis media [35,36,41,42]. Common isolates include *Staphylococcus intermedius*, *Pseudomonas aeruginosa*, β -hemolytic *Streptococcus*, *Proteus* spp, *Streptococcus canis*, and *Escherichia coli*. Because of multidrug-resistant problems with

middle ear bacterial isolates, especially for *P aeruginosa*, empiric therapy of *P aeruginosa* infections is not recommended [41].

There are many complications related to TECA/LBO surgical procedures. Intraoperative hemorrhage is the major complication noted during the surgical procedure. In many instances, the hemorrhage is insignificant clinically but hampers the surgeon's ability to view the surgical site. There are several reports of severe intraoperative hemorrhage resulting in patient death, however [11,13]. Postoperative complications involve soft tissue complications and neurologic complications and can be further separated into acute and chronic complications. Soft tissue complications involve acute wound complications, pinna necrosis, and chronic fistulation. Neurologic complications include exacerbation of preoperative deficits, facial nerve deficits, hypoglossal nerve deficits, peripheral vestibular syndrome, and hearing loss. In many cases, these complications are temporary, and with proper treatment, there are no long-term sequelae to these problems [24]. Acute wound complications reported in the literature, ranging from 8% to 41%, include acute cellulitis/abscessation, incisional hematoma, incisional dehiscence, and extended wound drainage (Fig. 14) [11–14,22,43]. If complications develop, most are treated successfully with antibiotic therapy and local wound care until second intention healing occurs. Pinna necrosis is usually related to disturbance of the pinna vasculature during dissection and occurs along the proximal edge of the caudal pinna margin [24]. Therapy for this complication consists of debridement of the damaged tissue and open wound management until secondary intention healing occurs. The primary long-term soft tissue complication involves recurrent otitis media and the development of a draining tract. The most common underlying reason for recurrent infection is incomplete removal of the secretory epithelium lining the tympanic bulla [12,22,24]. Other factors include osteomyelitis of the ossicles,

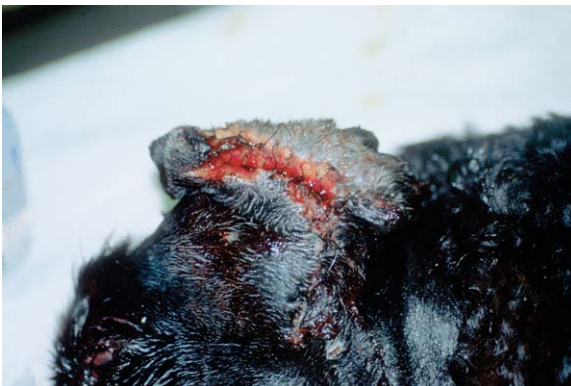

Fig. 14. An example of incisional dehiscence and abscessation 3 days after total ear canal ablation and lateral bulla osteotomy.

inadequate drainage of the middle ear through the Eustachian tube, and parotid salivary gland damage [21]. Even with performance of a lateral bulla osteotomy and proper curettage of the tympanic bulla, the rate of recurrent infection is 5% to 10% [11–14,22]. Antibiotic therapy is usually not successful in the treatment for recurrence of infection, and surgical exploration of the region is indicated [21]. Surgical approaches used for re-exploration of the middle ear include a lateral approach and LBO as well as a ventral approach and ventral bulla osteotomy [21,44]. The lateral approach may result in more complications associated with facial nerve deficits after surgery, although in most cases, the deficits were temporary [44]. Another chronic complication noted in some studies is ongoing superficial dermatitis of the pinna, which is most likely secondary to an underlying dermatologic problem.

Clinical signs of either facial nerve deficits or peripheral vestibular syndrome are commonly noted during the preoperative evaluation, and owners should be alerted to these deficits because most do not completely resolve with surgery [24]. In many instances, the facial nerve or branches are damaged during dissection around the ear canal during surgery. This damage can be associated with the dissection process or with retraction. Clinical signs associated with facial paresis/paralysis include slow/absent palpebral reflex and hemifacial paresis leading to drooping of the ipsilateral eye and lip margins [13,14,22]. Eye lubricants (artificial tears or ointments) are recommended to reduce the chance of corneal abrasion or ulceration until the affected eye regains normal function. In 10% to 15% of cases, there is permanent facial nerve damage; however, there is not a need for long-term protection of the globe, because continued lacrimal function, passive movement of the third eyelid (cranial nerve VI), and abducens nerve-mediated globe retraction are sufficient to ensure a proper corneal tear film [11,22]. In most cases, careful dissection and identification of the facial nerve and its branches decrease the extent of neurologic deficits. Vestibular deficits, including postural abnormalities, nystagmus, and head tilt, are also noted in the postoperative period and are a result of excessive and inappropriate curettage of the dorsomedial region of the bulla in most cases. The overall rate of vestibular deficits is reported to range from 2% to 30%, but such deficits are usually temporary if they were not present in the preoperative period [22,24]. Interruption of the oculosympathetic pathways resulting in Horner's syndrome tends to occur only in the feline patient [13]. Hypoglossal deficits have been reported and are associated with either making a ventral approach to the bulla or excessive ventral dissection of the tympanic bulla [11,23]. Finally, hearing loss associated with TECA/LBO is a consistent complication noted in many studies. Subjectively, if owners are made aware of their pet's auditory deficits in the preoperative evaluation, there is a low percentage of owners who believe that the auditory function decreased in the postoperative period [24]. The results of BAER testing performed on dogs with chronic otitis externa/media are in agreement with

the subjective observations in many cases, because these dogs seem to have limited hearing ability in the preoperative period compared with normal dogs, and this hearing is through bone conduction in many cases. Overall, most complications noted, both soft tissue and neurologic, tend to be of a limited duration and respond to conservative therapy in many cases.

TECA with LBO is also performed in the feline patient. Cats with aural tumors, such as ceruminous gland adenoma, adenocarcinoma, squamous cell carcinoma (SCC), basal cell carcinoma, and trauma or avulsion of the external ear canal are generally considered candidates for the procedure [13,16,18,19,24,45]. TECA/LBO performed for chronic otitis externa and media is rare in the feline patient [24]. Complication rates for feline TECA/LBO are similar to canine complication rate, although some studies suggest that there is a greater incidence of neurologic complications, especially permanent facial nerve deficits, despite meticulous surgical dissection [46].

In general, the overall prognosis for animals with TECA/LBO performed for chronic otitis externa and media is favorable. Many owners have also noted a significant improvement in the demeanor of the pets, level of activity, and willingness to play, which all enhance the human-animal bond [11].

Feline pinna squamous cell carcinoma

SCC is a common feline skin neoplasia that often affects the pinna, nasal planum, eyelids, and periauricular regions [47]. White cats have a 13.4 times greater chance of developing SCC than cats with pigmentation of these regions [47]. The cause of this disease in white cats is thought to involve exposure to ultraviolet radiation (UVA/UVB) from normal sunlight [47]. One possible connection between ultraviolet light and tumorigenesis involves a mutation of the tumor suppressor gene p53, which was noted in 9 of 11 cats with SCC involving the pinna [48,49]. There have also been studies that have tried to determine if there is any correlation between infection with feline leukemia virus (FeLV) or feline immunodeficiency virus (FIV) and development of SCC, although there is no causative stimulus thought to exist [50]. Recently, antigens specific for papillomavirus groups were demonstrated in feline multicentric SCC *in situ* lesions by immunohistochemical methods [51].

The biologic activity of feline pinna SCC tends to be locally invasive, but it does not tend to metastasize to either local lymph nodes or the lungs in most cases [52,53]. With continued growth, however, these tumors can be irritating to the cat and lead to cosmetic concerns for owners or even loss of function. In addition to local recurrence from inadequate therapy, *de novo* development of SCC in other regions of the face is common [54].

There are a wide variety of options for treatment of feline pinna SCC. Superficial tumors, either T1 or T2 tumors (Table 1), can usually be managed using an array of surgical techniques with equal effectiveness,

Table 1
Clinical stages of feline tumors of epidermal origin

Site	Stage	Definition
Primary tumor	T _{is}	Preinvasive carcinoma (carcinoma in situ)
	T ₀	No evidence of tumor
	T ₁	Tumor <2 cm in maximal diameter, superficial or exophytic
	T ₂	Tumor 2–5 cm in maximal diameter or minimal invasion regardless of size
	T ₃	Tumor >5 cm in maximal diameter or with invasion of the subcutis, irrespective of size
	T ₄	Tumor invades deeper structures (fascia, muscle, bone, or cartilage)
Regional lymph nodes	N ₀	No evidence of regional lymph node involvement
Distant metastasis	M ₀	No evidence of distant metastasis

Data from Owen L. TNM classification of tumors in domestic animals. Geneva: World Health Organization; 1980.

including blade excision, electrocautery, and laser excision [52,54–56]. Other modalities that have been used for local control include cryotherapy, hyperthermia therapy, external beam radiation therapy, and photodynamic therapy [52,57–61]. A pinnectomy can be performed using blade excision, electrocautery, or a carbon dioxide laser and can be either subtotal or total if there is evidence of more invasive or extensive involvement of the pinna. After the hair is clipped from the region of interest and the surgical site is prepared, a noncrushing hemostat (ie, Doyen's intestinal forceps) is placed across the pinna to decrease hemorrhage and act as a cutting template to ensure cosmetic symmetric results. The involved region is then removed with a scalpel blade or carbon dioxide laser unit. The remaining skin edges are apposed with a simple continuous pattern of 3-0/4-0 chromic gut over the cartilage. Wide surgical margins (1–2 cm) should be attained because of the locally aggressive nature of this neoplasia. With complete excision, the long term-prognosis for surgical resection of pinna SCC ranges from 19 to 22 months for a median disease-free interval and a median survival time of 799 days [52,55].

Local therapies that do not involve surgical excision include cryotherapy, laser ablation, radiation therapy, and photodynamic therapy. Cryosurgery is a modality that is useful for lesions less than 0.5 mm or in regions that are difficult to access for anatomic reasons [62]. Two freeze-thaw cycles should be completed to ensure maximal destruction of neoplastic cells. A recent study found that 83% of cats with facial SCC had total remission after treatment with cryosurgery. All pinna lesions resolved with a single treatment. In general, there was an 84% remission rate at 12 months, and 81% of the cats continued to be tumor-free at 36 months; no cats with SCC of the pinna had recurrence [57]. Results of cryotherapy in another study resulted in a 73% recurrence rate (8 of 11 cats), however, and a median disease-free interval of only 184 days [52]. Radiation therapy is an effective tool for control of feline

SCC, although in veterinary studies, the use of radiation therapy has been limited to nasal SCC [52,62]. Photodynamic therapy involves either the systemic or topical administration of a compound that is preferentially absorbed by neoplastic cells. This compound acts as a photosensitizer; when the tissue is exposed to a certain wavelength, there is localized formation of cytotoxic free radicals. Similar to other modalities, the use of photodynamic therapy for SCC seems to be correlated to the size and invasive nature of the tumor; the response for small aural tumors is reportedly quite good (100% remission with one treatment) [59]. Finally, chemotherapy with both cytotoxic and noncytotoxic agents is used for the treatment of feline SCC. Cytotoxic agents used include intralesional and systemic chemotherapy. In general, the systemic chemotherapy agents for feline SCC are not shown to be efficacious, although various agents, including bleomycin, carboplatin, and doxorubicin, have been evaluated [63–65].

In general, SCC of the feline pinna can usually be treated with aggressive local control with a good outcome. Owners need to be counseled on the cosmetic outcome and the chance for possible local recurrence. Additionally, the importance of frequent re-evaluations and early treatment of recurrence needs to be stressed.

Feline nasopharyngeal polyps

Feline nasopharyngeal polyps (FNPs) are a common cause of nasopharyngeal disease and the most common external ear canal masses seen in the feline patient [66–68]. FNPs are nonneoplastic masses that arise from the mucosal lining of the nasopharynx, Eustachian (auditory) tube, or tympanic bulla [66,69,70]. The cause of the FNPs is still to be determined but is thought to be related to an inflammatory response to a concurrent infection. Although bacterial and fungal agents have been identified within polyp tissue, a pyogranulomatous reaction to feline calicivirus was thought to be the inciting infectious agent [71]. Feline coronavirus (FCV) and feline herpes virus (FHV-1) were not detected in one case series, however. Potential explanations for the lack of viral particles include the possibility that the viruses are either not associated with polyp formation or that although FHV-1 or FCV infection is necessary for initiation of the polyp, as inflammation progresses and the infection potentially clears, the continued inflammatory response is independent of the presence of viral particles [72]. A possible congenital cause for the development of FNPs involves remnants of the brachial arches [71]. FNPs appear as oval to oblong masses and can either be pedunculated or sessile in nature. They tend to be pale gray, white, or pink in color but become red if inflamed or traumatized. The histologic description of FNPs usually includes reference to regions of well-vascularized fibrous connective tissue covered with either stratified squamous or columnar epithelium. A variety of inflammatory cells, including lymphocytes, plasma cells, and macrophages, are commonly noted in the histologic sections [66].

FNPs are most commonly noted in cats less than 2 years old, but there are numerous reports of occurrences in older animals [66,68,70,73,74]. There does not seem to be any sex or breed disposition [66,75]. Clinical signs include chronic nasal discharge, stertorous respirations, sneezing, dyspnea, dysphagia, and exercise intolerance. If the polyp extends to the external ear canal, clinical signs associated with otitis are most commonly noted. Neurologic signs intermittently associated with local extension of the inflammation include signs of peripheral vestibular syndrome or Horner's syndrome. Clinical signs may be present for variable time frames ranging from relatively acute to chronic, and the severity of clinical signs is likely a result of the extent and location of the polyp. Identification of nasopharyngeal polyps can be a relatively straightforward diagnosis. Nevertheless, there are a variety of differential diagnoses that should be considered, including nasopharyngeal abscess, infectious rhinitis (bacterial, viral, or fungal), lymphoplasmacytic rhinitis, nasal foreign bodies, cryptococcosis, nasopharyngeal stenosis, brachycephalic syndrome (Persian breeds), neoplastic lesions, laryngeal paralysis, inflammatory laryngeal disease, laryngospasm, and upper respiratory tract cysts [67,68,76]. Diagnosis of FNPs involves a combination of physical examination findings, radiographic studies, endoscopy, and pathologic evaluation. Oral examination may reveal ventral displacement of the soft palate with firm resistance to digital pressure. Ooscopic evaluation can be performed in the awake animal to determine if there is evidence of otitis; in some cases, polyp tissue can be seen behind the tympanic membrane. The remainder of the diagnostic evaluation is performed under general anesthesia. The oral examination can be continued by rostral retraction of the soft palate using a Snook spay hook [66] to visualize the caudal nasopharynx (Fig. 15). Radiographic studies include a survey skull series, cervical and thoracic

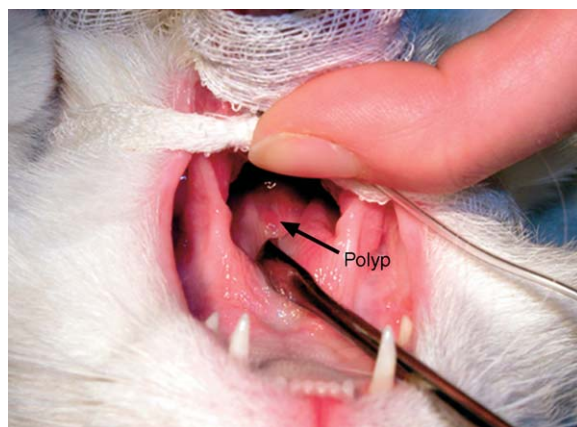


Fig. 15. A snay hook can be used to retract the soft palate in a rostral direction to visualize the nasopharyngeal region.

radiographs, CT, and MRI. FNPs are often noted on the lateral projection as soft tissue opacities located within the nasopharynx. The tympanic bulla can be evaluated with the use of the lateral oblique and rostral-caudal open-mouth views (Figs. 16 and 17). CT and MRI evaluation of the tympanic bulla for evidence of otitis media is becoming a popular alternative to survey radiographs because of an approximate false-negative rate of 20% to 25% in animals with proven otitis media [31,74,77]. Histopathology is necessary to differentiate nasopharyngeal polyps from other causes, such as neoplasia.

Treatment for nasopharyngeal polyps includes traction-avulsion of the mass or surgical management. Surgical management usually consists of a ventral bulla osteotomy but may also include an LBO depending on the location of the mass. Polyps can recur in up to 17% to 50% of animals treated with traction alone; A decreased recurrence rate is noted in animals that are treated surgically [66,70,73,74,78,79]. Traction removal of the polyp is performed under general anesthesia. In most cases, the soft palate does not need to be incised for additional surgical exposure. The stalk of the polyp is isolated using hemostats, Allis tissue forceps, or right-angle forceps. Gentle traction and rotation of the instrument usually result in avulsion of the polyp. There should be a tapered stalk to the polyp if the entire polyp is avulsed from its origin (Fig. 18). One anatomic feature of importance of the feline bulla is the septum dividing the tympanic bulla into a larger ventromedial compartment and a smaller dorsolateral compartment. Another region of surgical importance is the promontory, an osseous process along the dorsomedial aspect of the bulla along which the sympathetic nerve fibers run. The ventromedial compartment contains the round window, which should be avoided when curettage is performed. The dorsolateral compartment contains the tympanic membrane and auditory ossicles, which are located along the lateral portion of the compartment

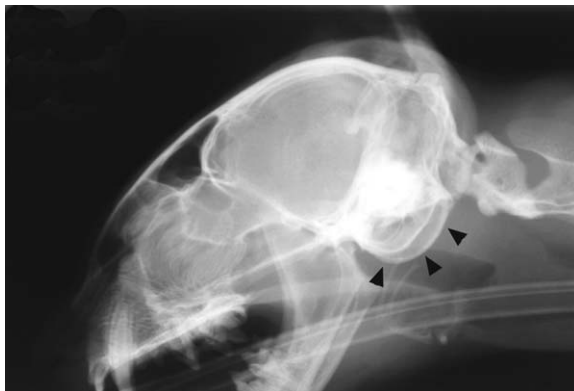


Fig. 16. Lateral radiograph of a cat with an inflammatory polyp. Note the thickened wall of the bulla (arrowheads).

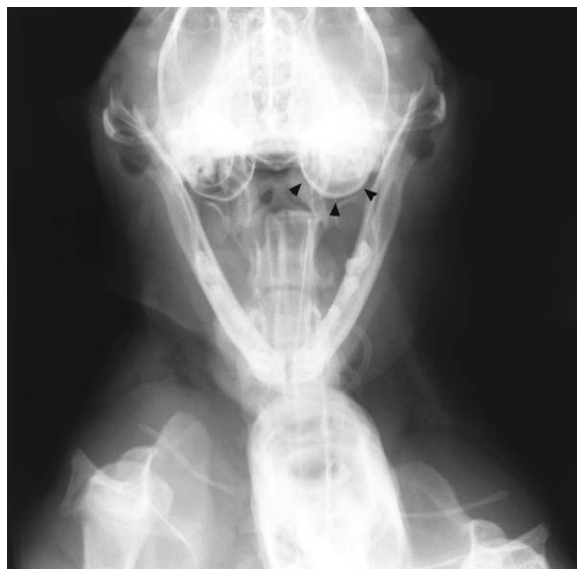

Fig. 17. Frontal open-mouth projection showing opacification and thickening of the bulla (arrowheads).

[66,78]. Important neurovascular structures located in proximity to the tympanic bulla include the internal carotid artery, facial nerve, hypoglossal nerve, and lingual artery and vein [66,78].

In most cases, surgical intervention involves performing a ventral bulla osteotomy. The patient is placed in dorsal recumbency with the head extended and stabilized. In most feline patients, the bulla is palpable caudal

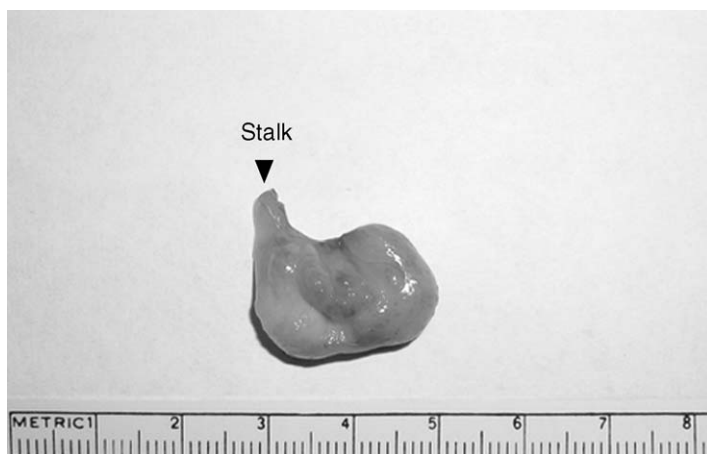

Fig. 18. There should be a tapered stalk to the polyp if the entire polyp is avulsed from its origin.

to the mandible. A cranial-to-caudal incision is made over the region of the bulla. Anatomic structures to be cognizant of include the hypoglossal nerve and lingual artery, which are retracted medially, and the dissection is continued medial to the digastricus muscle. Self-retaining retractors are placed once the ventral surface of the bulla is exposed. Using either a large Steinmann pin and Jacob's chuck or a high-speed burr, the larger ventrolateral portion of the bulla is entered (Fig. 19). The ventral portion of the bulla is removed using rongeurs or the burr. Bacterial culture and sensitivity samples can be collected at this time. The septum between the two compartments is opened. The region of the promontory should be avoided because of the sympathetic fibers that travel through this region. The bulla contents can be removed using a combination of traction and curettage and submitted for histopathologic evaluation. The remainder of the bulla epithelial lining is removed using gentle curettage and flushed with sterile saline. A passive (Penrose drain) or active (butterfly catheter with vacuum tube) drain is placed before closure of the wound.

Postoperative management consists of monitoring the patient for any evidence of dyspnea as a result of edema secondary to the polyp traction or surgical manipulation of tissues. Patients should be kept maintained on intravenous fluids until they are eating and drinking. Empiric antibiotic therapy can be considered until results of the culture and sensitivity testing are returned. The number of animals with positive middle ear cultures is extremely variable in clinical reports, ranging from 13% to 83% [70,74,79]. Most surgeons routinely administer a course of antibiotics based on culture

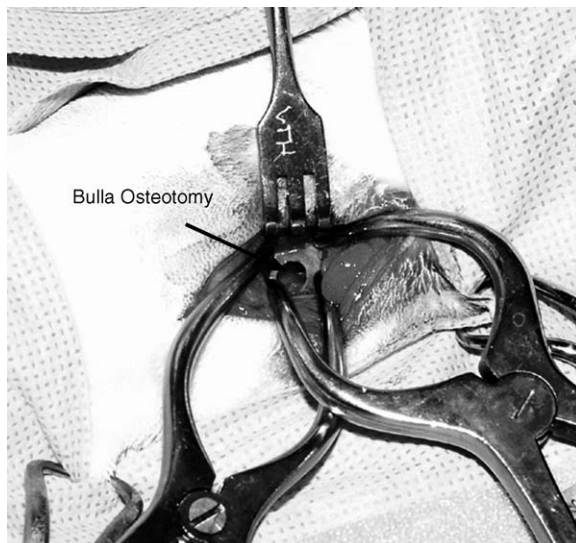

Fig. 19. Using either a Steinmann pin and Jacob's chuck or a high-speed burr, the larger ventrolateral portion of the bulla is entered.

and sensitivity results or empiric therapy, however. The use of corticosteroids has been recommended in one report to decrease the incidence of polyp recurrence; however, their use is controversial, and routine use is discouraged by most sources unless postoperative pharyngeal edema is present [66,73].

Complications are generally divided into neurologic and nonneurologic complications. Neurologic complications are the primary complications noted with surgical intervention. Horner's syndrome is noted commonly in the postoperative period (up to 80%) and is temporary in most cases [66,74,78]. Clinical signs are usually caused by disruption of the sympathetic nerve fibers that are exposed along the promontory and ventromedial portion of the tympanic bulla and can be seen with traction avulsion removal of the polyps as well [78]. Facial nerve paralysis is another possible neurologic complication secondary to surgical intervention [46,73,79]. Peripheral vestibular syndrome, consisting of nystagmus, head tilt, and ataxia, can occur as a result of aggressive curettage of the dorsomedial portion of the tympanic cavity and is temporary in most cases [70,78]. If neurologic deficits are noted during the preoperative evaluation, however, the owners should be made aware that these signs might not improve with surgical intervention [79]. Hypoglossal nerve deficits are another reported neurologic complication associated with a ventral bulla osteotomy [66,78]. The primary non-neurologic complication noted with surgical intervention and the traction avulsion technique is recurrence of the inflammatory polyp. Recurrence of inflammatory polyps is higher after traction avulsion treatment (in 13 of 31 cats for a 42% total reported recurrence rate) than after surgical intervention (3 of 46 cats for a 6% total reported recurrence rate) [70,73,74,79]. Therefore, even with the increased risk, a ventral bulla osteotomy should be recommended. Other complications associated with traction and avulsion or ventral bulla osteotomy include recurrent otitis media/interna, pharyngeal swelling, and incisional drainage. In general, the prognosis for successful treatment of a feline inflammatory polyp is good to excellent. Recurrence is rarely seen if proper surgical techniques are adhered to, and although complications are recognized, they are mild and of a temporary nature.

References

- [1] Swaim SF, Bradley DM. Evaluation of closed-suction drainage for treating auricular hematomas. *J Am Anim Hosp Assoc* 1996;32(1):36–43.
- [2] Romatowski J. Nonsurgical treatment of aural hematomas. *J Am Vet Med Assoc* 1994; 204(9):1318.
- [3] Leftwich MW, Carey DP. Cyanoacrylate adhesive for aural hematoma. *Vet Med Small Anim Clin* 1981;76(8):1155.
- [4] Joyce JA, Day MJ. Immunopathogenesis of canine aural haematoma. *J Small Anim Pract* 1997;38(4):152–8.
- [5] Kuwahara J. Canine and feline aural hematoma: clinical, experimental, and clinicopathologic observations. *Am J Vet Res* 1986;47(10):2300–8.

- [6] Dye TL, Teague HD, Ostwald DA Jr, Ferreira SD. Evaluation of a technique using the carbon dioxide laser for the treatment of aural hematomas. *J Am Anim Hosp Assoc* 2002; 38(4):385–90.
- [7] Horne RD, Henderson RA. Pinna. In: Slatter D, editor. *Textbook of small animal surgery*. 3rd edition. Philadelphia: WB Saunders; 2003. p. 1737–45.
- [8] Sylvestre AM. Potential factors affecting the outcome of dogs with a resection of the lateral wall of the vertical ear canal. *Can Vet J* 1998;39(3):157–60.
- [9] Krahwinkel DJ. External ear canal. In: Slatter D, editor. *Textbook of small animal surgery*. 3rd edition. Philadelphia: Saunders; 2003. p. 1746–56.
- [10] Seward C, Blackmore W, Ott R. Treatment of chronic canine otitis externa by ablation of the ear canal. *J Am Vet Med Assoc* 1958;133:417–9.
- [11] Mason LK, Harvey CE, Orsher RJ. Total ear canal ablation combined with lateral bulla osteotomy for end-stage otitis in dogs. Results in thirty dogs. *Vet Surg* 1988;17(5):263–8.
- [12] Beckman SL, Henry WB Jr, Cechner P. Total ear canal ablation combining bulla osteotomy and curettage in dogs with chronic otitis externa and media. *J Am Vet Med Assoc* 1990;196(1):84–90.
- [13] Smeak DD, DeHoff WD. Total ear canal ablation: clinical results in the dog and cat. *Vet Surg* 1986;15(2):161–70.
- [14] Matthiesen DT, Scavelli T. Total ear canal ablation and lateral bulla osteotomy in 38 dogs. *J Am Anim Hosp Assoc* 1990;26:257–67.
- [15] McCarthy PE, Hosgood G, Pechman RD. Traumatic ear canal separations and para-aural abscessation in three dogs. *J Am Anim Hosp Assoc* 1995;31(5):419–24.
- [16] Moisan PG, Watson GL. Ceruminous gland tumors in dogs and cats: a review of 124 cases. *J Am Anim Hosp Assoc* 1996;32(5):448–52.
- [17] Marino D, MacDonald J, Matthiesen DT, et al. Results of surgery and long-term follow-up in dogs with ceruminous gland adenocarcinoma. *J Am Anim Hosp Assoc* 1993;29:560–3.
- [18] Marino D, MacDonald J, Matthiesen DT, et al. Results of surgery in cats with ceruminous gland adenocarcinoma. *J Am Anim Hosp Assoc* 1994;30:54–8.
- [19] London CA, Dubilzeig RR, Vail DM, Ogilvie GK, Hahn KA, Brewer WG, et al. Evaluation of dogs and cats with tumors of the ear canal 145 cases 1978–1992. *J Am Vet Med Assoc* 1996;208(9):1413–8.
- [20] House A. Atresia of the distal external acoustic meatus in a Bouvier des Flandres. *J Small Anim Pract* 2001;42(2):88–9.
- [21] Smeak DD, Crocker CB, Birchard SJ. Treatment of recurrent otitis media that developed after total ear canal ablation and lateral bulla osteotomy in dogs: nine cases (1986–1994). *J Am Vet Med Assoc* 1996;209(5):937–42.
- [22] White RA, Pomeroy CJ. Total ear canal ablation and lateral bulla osteotomy in the dog. *J Small Anim Pract* 1990;31:547–53.
- [23] Sharp NJ. Chronic otitis externa and otitis media treated by total ear canal ablation and ventral bulla osteotomy in thirteen dogs. *Vet Surg* 1990;19(2):162–6.
- [24] Smeak DD, Kerpsack SJ. Total ear canal ablation and lateral bulla osteotomy for management of end-stage otitis. *Semin Vet Med Surg (Small Anim)* 1993;8(1):30–41.
- [25] Angus JC, Lichtensteiger C, Campbell KL, Schaeffer DJ. Breed variations in histopathologic features of chronic severe otitis externa in dogs: 80 cases (1995–2001). *J Am Vet Med Assoc* 2002;221(7):1000–6.
- [26] Kern T, Hollis N. Facial neuropathy in dogs and cats. 95 cases (1975–1985). *J Am Vet Med Assoc* 1987;191:1604–9.
- [27] Schunk K, Averill D. Peripheral vestibular syndrome in the dog: a review of 83 cases. *J Am Vet Med Assoc* 1983;182:1354–7.
- [28] Spangler EA, Dewey CW. Meningoencephalitis secondary to bacterial otitis media/interna in a dog. *J Am Anim Hosp Assoc* 2000;36:239–43.
- [29] Sims MH. Electrodiagnostic evaluation of auditory function. *Vet Clin North Am Small Anim Pract* 1988;18:913–44.

- [30] Krahwinkel DJ, Pardo AD, Sims MH, Bubb WJ. Effect of total ablation of the external acoustic meatus and bulla osteotomy on auditory function in dogs. *J Am Vet Med Assoc* 1993;202(6):949–52.
- [31] Remedios AM, Fowler JD, Pharr JW. A comparison of radiographic versus surgical diagnosis of otitis media. *J Am Anim Hosp Assoc* 1991;27:183–8.
- [32] Eom K, Lee H, Yoon J. Canalographic evaluation of the external ear canal in dogs. *Vet Radiol Ultrasound* 2000;41(2):231–4.
- [33] Trower ND, Gregory SP, Renfrew H, Lamb CR. Evaluation of the canine tympanic membrane by positive contrast ear canalography. *Vet Rec* 1998;142:78–81.
- [34] Dvir E, Kirberger R, Terblanche A. Magnetic resonance imaging of otitis media in a dog. *Vet Radiol Ultrasound* 2000;41(1):46–9.
- [35] Vogel PL, Komtebedde J, Hirsh DC, Kass PH. Wound contamination and antimicrobial susceptibility of bacteria cultured during total ear canal ablation and lateral bulla osteotomy in dogs. *J Am Vet Med Assoc* 1999;214(11):1641–3.
- [36] Colombini S, Merchant SR, Hosgood G. Microbial flora and antimicrobial susceptibility patterns from dogs with otitis media. *Vet Dermatol* 2000;11:235–9.
- [37] Devitt CM, Seim HB III, Willer R, McPherron M, Neely M. Passive drainage versus primary closure after total ear canal ablation–lateral bulla osteotomy in dogs: 59 dogs (1985–1995). *Vet Surg* 1997;26(3):210–6.
- [38] Buback JL, Boothe HW, Carroll GL, Green RW. Comparison of three methods for relief of pain after ear canal ablation in dogs. *Vet Surg* 1996;25(5):380–5.
- [39] Radlinsky M, Mason D, Roush J, et al. Continuous infusion of bupivacaine for analgesia following total ear canal ablation in dogs [abstract]. Presented at the 12th Annual Veterinary Symposium of the American College of Veterinary Surgeons, San Diego, October, 2002.
- [40] Herring I, Pickett J, Champagne E, Marini M. Evaluation of aqueous tear production in dogs following general anesthesia. *J Am Anim Hosp Assoc* 2000;36:427–30.
- [41] Petersen AD, Walker RD, Bowman MM, Schott HC, Rosser EJ. Frequency of isolation and antimicrobial susceptibility patterns of *Staphylococcus intermedius* and *Pseudomonas aeruginosa* isolates from canine skin and ear samples over a 6 year period (1992–1997). *J Am Anim Hosp Assoc* 2002;38:407–13.
- [42] Cole LK, Kwochka KW, Kowalski JJ, Hillier A. Microbial flora and antimicrobial susceptibility patterns of isolated pathogens from the horizontal ear canal and middle ear in dogs with otitis media. *J Am Vet Med Assoc* 1998;212(4):534–8.
- [43] Lane JG, Little JL. Surgery of the canine external auditory meatus: a review of failures. *J Small Anim Pract* 1986;27:247–54.
- [44] Holt DE, Brockman DJ, Sylvestre AM, Sadanaga KK. Lateral exploration of the fistulas developing after total ear canal ablations: 10 cases (1989–1993). *J Am Anim Hosp Assoc* 1996;32:527–30.
- [45] Day DG, Couto CG, Weisbrode SW, Smeak DD. Basal cell carcinoma in two cats. *J Am Anim Hosp Assoc* 1994;30:265–9.
- [46] Williams J, White R. Total ear canal ablation combine with lateral bulla osteotomy in the cat. *J Small Anim Pract* 1992;33:225–7.
- [47] Dorn C. Epidemiology of canine and feline tumors. *J Am Anim Hosp Assoc* 1976;12:307–12.
- [48] Teifke JP, Lohr CV. Immunohistochemical detection of p53 overexpression in paraffin embedded squamous cell carcinoma. *J Comp Pathol* 1996;114:205–10.
- [49] Brash DE, Rudolph JA, Simon JA, et al. A role for sunlight in skin cancer: UV-induced p53 mutations in squamous cell carcinoma. *Proc Natl Acad Sci USA* 1991;88:10124–8.
- [50] Hutson CA, Rideout BA, Pedersen NC. Neoplasia associated with feline immunodeficiency virus infection in cats of southern California. *J Am Vet Med Assoc* 1991;199:1357–62.
- [51] LeClerc SM, Clark EG, Haines DM. Papillomavirus infection in association with feline cutaneous squamous cell carcinoma in situ. Presented at the 13th Annual Members'

- Meeting of the American Academy of Veterinary Dermatology and American College of Veterinary Dermatology, Nashville, TN, April, 1997.
- [52] Lana SE, Ogilvie GK, Withrow SJ, Straw RC, Rogers KS. Feline cutaneous squamous cell carcinoma of the nasal planum and the pinnae: 61 cases. *J Am Anim Hosp Assoc* 1997; 33(4):329–32.
- [53] Hargis AM. A review of solar induced lesions in domestic animals. *Compend Contin Educ Pract Vet* 1981;3:287–94.
- [54] Macy DW, Reynolds HA. The incidence, characteristics and clinical management of skin tumors in cats. *J Am Anim Hosp Assoc* 1981;17:1026–34.
- [55] Atwater SW, Powers BE, Straw RC, Withrow SJ. Squamous cell carcinoma of the pinna and nasal planum. Fifty-four cats (1980–1991). *Proc Annu Conf Vet Cancer Soc* 1991;11: 35–6.
- [56] Shelley BA, Bartels KE, Ely RW. Use of the neodymium:yttrium-aluminum-garnet laser for treatment of squamous cell carcinoma in a cat. *J Am Vet Med Assoc* 1992;201:756–8.
- [57] Clarke RE. Cryosurgical treatment of feline cutaneous squamous cell carcinoma. *Aust Vet Pract* 1991;21:148–53.
- [58] Magne ML, Rodriquez CO, Autry SA, Edwards BF, Theon AP, Madewell BR. Photodynamic therapy of facial squamous cell carcinoma in cats using a few photosensitizer. *Lasers Surg Med* 1997;20(2):202–9.
- [59] Peaston AE, Leach MW, Higgins RJ. Photodynamic therapy for nasal and aural squamous cell carcinoma in cats. *J Am Vet Med Assoc* 1993;202(8):1261–5.
- [60] Stell AJ, Dobson JM, Langmack K. Photodynamic therapy of feline superficial squamous cell carcinoma using topical 5-aminolaevulinic acid. *J Small Anim Pract* 2001;42(4):164–9.
- [61] Grier RL, Brewer WG, Theilen GH. Hyperthermic treatment of superficial tumors in cats and dogs. *J Am Vet Med Assoc* 1980;177(3):227–32.
- [62] Ruslander D, Kaser-Hotz B, Sardinas JC. Cutaneous squamous cell carcinoma in cats. *Compend Contin Educ Pract Vet* 1997;19(10):1119–29.
- [63] Buhles W, Theilen GH. Preliminary evaluation of bleomycin in feline and canine squamous cell carcinoma. *Am J Vet Res* 1973;34:289–91.
- [64] Kisserberth W, Vail D, Jeglum K, et al. Evaluation of carboplatin in tumor bearing cats: a phase I study from the Veterinary Cooperative Oncology Group. In: *Proceedings of the 16th Annual Meeting of the Veterinary Cancer Society*. 1996. p. 39–40.
- [65] Maudlin G, Matus R, Patnaik A, et al. Efficacy and toxicity of doxorubicin and cyclophosphamide used in the treatment of selected malignant tumors in 23 cats. *J Vet Intern Med* 1988;46:60–5.
- [66] Pope ER. Feline inflammatory polyps. *Semin Vet Med Surg (Small Anim)* 1995;10(2): 87–93.
- [67] Hunt G, Perkins M, Foster S, et al. Nasopharyngeal disorders of dogs and cats: a review and retrospective study. *Compend Contin Educ Pract Vet* 2002;24(3):184–200.
- [68] Allen H. Nasopharyngeal disease in cats: a retrospective study of 53 cases (1991–1998). *J Am Anim Hosp Assoc* 1999;35:457–61.
- [69] Bedford P. Origin of the nasopharyngeal polyp in the cat. *Vet Rec* 1982;110:541–2.
- [70] Faulkner J, Budsburg S. Results of ventral bulla osteotomy for treatment of middle ear polyps in cats. *J Am Anim Hosp Assoc* 1990;26:496–9.
- [71] Parker N, Binnington A. Nasopharyngeal polyps in cats: three case reports and a review of the literature. *J Am Anim Hosp Assoc* 1985;21:473–8.
- [72] Veir JK, Lappin MR, Foley JE, Getzy DM. Feline inflammatory polyps: historical, clinical, and PCR findings for feline calici virus and feline herpes virus-1 in 28 cases. *J Feline Med Surg* 2002;4(4):195–9.
- [73] Anderson DM, Robinson RK, White RA. Management of inflammatory polyps in 37 cats. *Vet Rec* 2000;147(24):684–7.
- [74] Kapatkin A, Matthiesen DT, Noone K, et al. Results of surgery and long-term follow-up in 31 cats with nasopharyngeal polyps. *J Am Anim Hosp Assoc* 1990;26:387–92.

- [75] Muilenburg RK, Fry TR. Feline nasopharyngeal polyps. *Vet Clin North Am Small Anim Pract* 2002;32(4):839–49.
- [76] Griffon D. Upper airway obstruction in cats: pathogenesis and clinical signs. *Compend Contin Educ Pract Vet* 2000;22(9):822–30.
- [77] Seitz S, Losonsky J, Marretta S. Computed tomographic appearance of inflammatory polyps in three cats. *Vet Radiol Ultrasound* 1996;37(2):99–104.
- [78] Boothe HW. Surgery of the tympanic bulla (otitis media and nasopharyngeal polyps). *Probl Vet Med* 1991;3(2):254–69.
- [79] Trevor PB, Martin RA. Tympanic bulla osteotomy for treatment of middle-ear disease in cats: 19 cases (1984–1991). *J Am Vet Med Assoc* 1993;202(1):123–8.