

Use of laterally placed vacuum drains for management of aural hematomas in five dogs

Michael M. Pavletic, DVM

Case Description—5 dogs (a Newfoundland, Golden Retriever, Shiba Inu, Staffordshire Terrier, and Vizsla) were referred for evaluation and treatment of unilateral aural hematomas within a week after their formation.

Clinical Findings—Aural hematomas involved the left (3) or right (2) ears.

Treatment and Outcome—With patients under anesthesia, the aural hematomas were approached surgically from the convex, or lateral, pinna surface. Two small incisions were used to position a vacuum drain into the incised hematoma cavity. The drain exited at the base of the pinna and adjacent cervical skin. The free end of the drain was attached to a vacuum reservoir for 18 to 21 days. Drains and skin sutures were removed at this time along with the protective Elizabethan collar. All hematomas resolved and surgical sites healed during the minimum 6-month follow-up period. Cosmetic results were considered excellent in 4 of 5 patients. Slight wrinkling of the pinna in 1 patient resulted from asymmetric enlargement of the cartilaginous walls of the hematoma, where vacuum application resulted in a slight folding of the redundant lateral cartilage wall.

Clinical Relevance—The described treatment was efficient, economical, and minimally invasive and required no bandaging or wound care. Placement of the drain tubing on the convex (lateral) aspect sheltered the system from displacement by patients with an Elizabethan collar in place. Overall cosmetic results were excellent; asymmetric enlargement of the cartilaginous walls of the hematoma with slight folding of the pinna was seen in 1 patient. (*J Am Vet Med Assoc* 2014;246:112–117)

Five canine patients (a 9.6-year-old sexually intact male Newfoundland [dog 1], a 5-year-old spayed female Golden Retriever [dog 2], a 10-year-old spayed female Shiba Inu [dog 3], a 10-year-old spayed female Staffordshire Terrier [dog 4], and a 13-year-old castrated male Vizsla [dog 5]) were referred to a veterinary medical center because of unilateral aural hematomas present for ≤ 1 week. Physical examination revealed that each patient was in overall good health. Hematomas involved the right (dogs 1 and 4) or left (dogs 2, 3, and 5) pinna. Results of hematologic and serum biochemical analyses were within the respective reference ranges or considered clinically acceptable.

All dogs received cefazolin sodium^a (20 mg/kg [9.1 mg/lb], IM) 1 hour prior to surgery. Each patient was premedicated with butorphanol tartrate^b (0.3 mg/kg [0.14 mg/lb], IM), midazolam^c (0.3 mg/kg, IM), and dexmedetomidine hydrochloride^d (7 μ g/kg [3.2 μ g/lb], IM), followed by induction of anesthesia with propofol^e (5.0 mg/kg [2.3 mg/lb], IV). Each dog was intubated, and anesthesia was maintained with isoflurane^f in oxygen. Lactated Ringer's solution^g was administered IV at a rate of 5.0 mL/kg/h for the duration of surgery.

Both sides of the involved pinna were clipped of fur, including the base of the ear and adjacent cervical skin. The ear was suspended with Babcock forceps to facilitate preparation

of the skin with chlorhexidine surgical scrub^h alternated with gauze sponges impregnated with sterile saline (0.9% NaCl) solution. The pinna and adjacent skin were then draped. A sterile, partially fenestrated drain was selected according to the size of the patient's hematoma; a 10-mm flat drainⁱ was placed for dog 1, 10F drains^j (approx 3.3 mm diameter) were placed for dogs 2 and 3, and 15F drains^k (approx 5.0 mm diameter) were placed for dogs 4 and 5 (Figure 1).




Figure 1—Photograph of 3 fenestrated silicone drains, including a 15F (approx 5-mm) round cardiothoracic drain^k (left), 10F (approx 3.3-mm) round wound drain^j (middle), and 10-mm flat wound drainⁱ (right). Notice that the fenestrations for the drain depicted on the left consist of linear channels and those of the remaining drains are round.

From the Department of Surgery, Angell Animal Medical Center, 350 S Huntington Ave, Boston, MA 02130.
Address correspondence to Dr. Pavletic (mpavletic@angell.org).

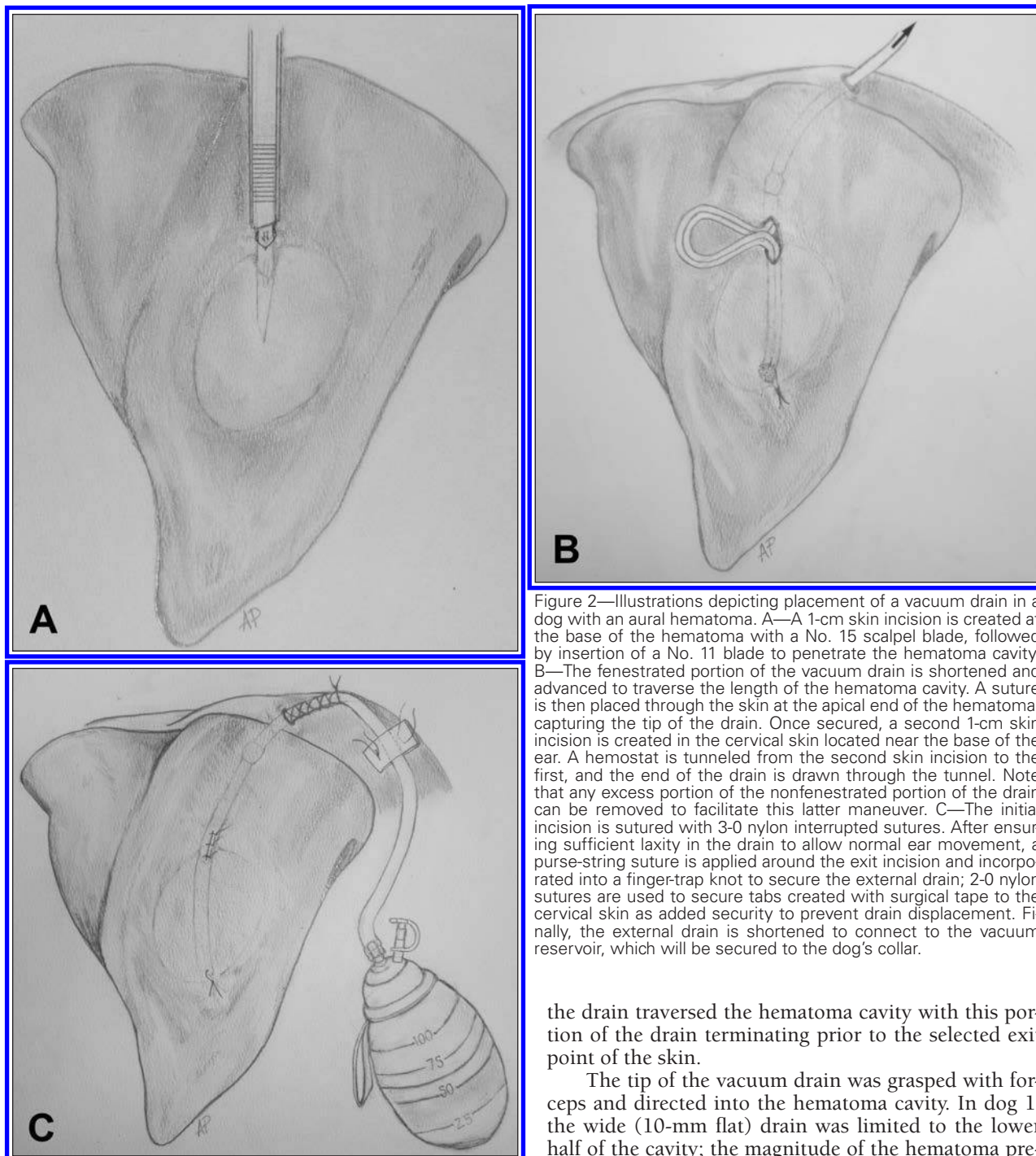


Figure 2—Illustrations depicting placement of a vacuum drain in a dog with an aural hematoma. A—A 1-cm skin incision is created at the base of the hematoma with a No. 15 scalpel blade, followed by insertion of a No. 11 blade to penetrate the hematoma cavity. B—The fenestrated portion of the vacuum drain is shortened and advanced to traverse the length of the hematoma cavity. A suture is then placed through the skin at the apical end of the hematoma, capturing the tip of the drain. Once secured, a second 1-cm skin incision is created in the cervical skin located near the base of the ear. A hemostat is tunneled from the second skin incision to the first, and the end of the drain is drawn through the tunnel. Note that any excess portion of the nonfenestrated portion of the drain can be removed to facilitate this latter maneuver. C—The initial incision is sutured with 3-0 nylon interrupted sutures. After ensuring sufficient laxity in the drain to allow normal ear movement, a purse-string suture is applied around the exit incision and incorporated into a finger-trap knot to secure the external drain; 2-0 nylon sutures are used to secure tabs created with surgical tape to the cervical skin as added security to prevent drain displacement. Finally, the external drain is shortened to connect to the vacuum reservoir, which will be secured to the dog's collar.

the drain traversed the hematoma cavity with this portion of the drain terminating prior to the selected exit point of the skin.

The tip of the vacuum drain was grasped with forceps and directed into the hematoma cavity. In dog 1, the wide (10-mm flat) drain was limited to the lower half of the cavity; the magnitude of the hematoma precluded the use of the only other drain (10F) available at this time, whereas the 10-mm flat drain was considered too wide to traverse the length of the cavity. In dogs 2 through 5, the tip of the drain was directed toward the limit of the cavity nearest the apex of the pinna. A single 3-0 nylon suture¹ was placed through the overlying skin, with the suture needle inserted through the center of the palpable drain tip before exiting the skin. The hemostat was withdrawn and the suture tied to assure the drain could not be displaced from the hematoma cavity. A smaller stab incision was made in the cervical skin adjacent to the base of the pinna. Metzenbaum scissors or a hemostat was used to bluntly dissect a narrow sub-

A 1-cm skin incision was created on the convex, or lateral, skin surface immediately below the base of the aural hematoma (aspect closest to the base of the ear), parallel to the long axis of the pinna, with a No. 15 scalpel blade. Care was taken to avoid incising major branches of the auricular vessels. A No. 11 scalpel blade was directed through the skin incision and into the base of the cartilage-encased hematoma cavity with a quick stabbing motion. The blade was withdrawn and a mosquito hemostat introduced into the hematoma incision to facilitate fluid evacuation. The fenestrated portion of a vacuum drain^{i-k} was shortened with scissors so that

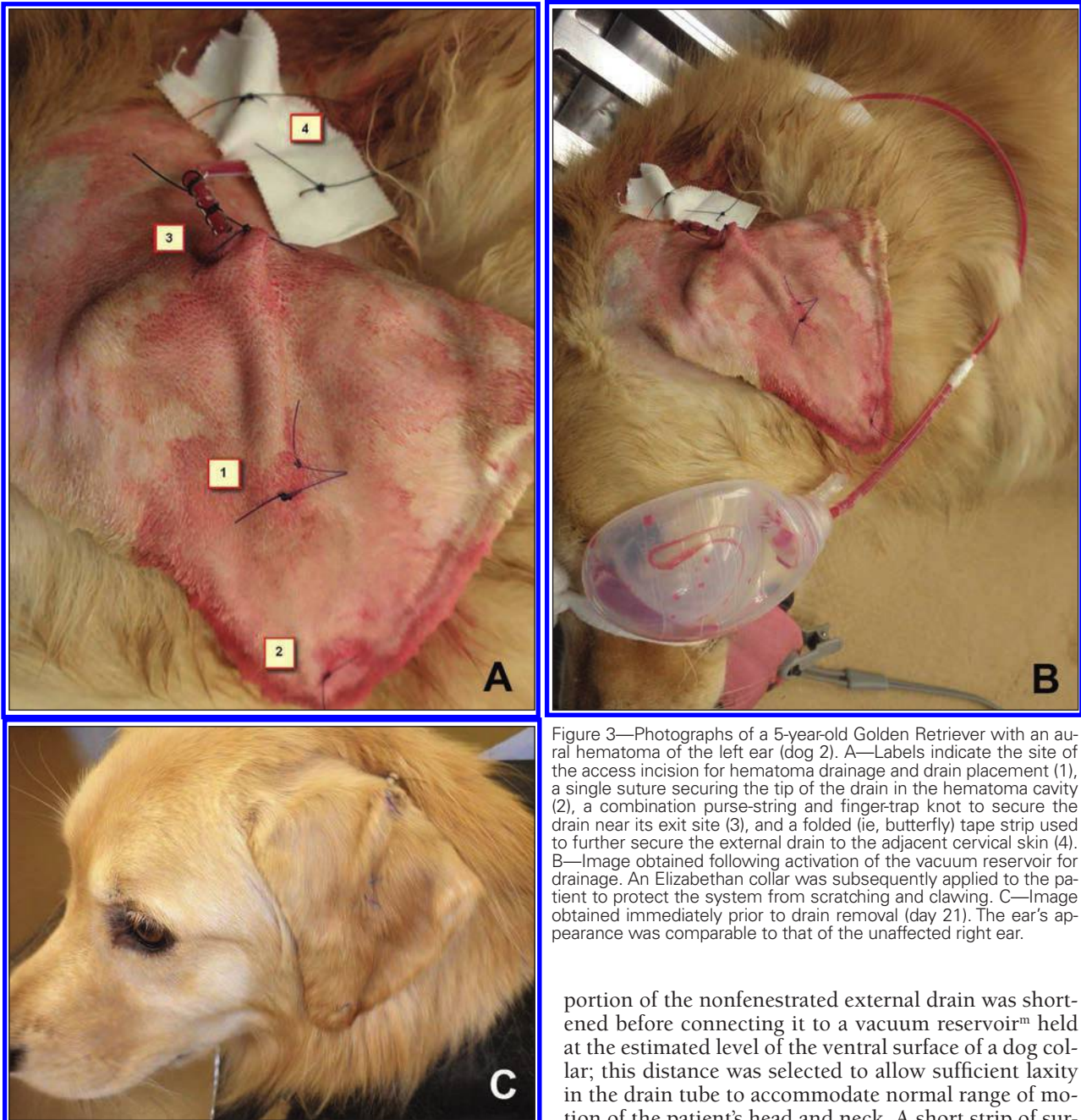


Figure 3—Photographs of a 5-year-old Golden Retriever with an auricular hematoma of the left ear (dog 2). A—Labels indicate the site of the access incision for hematoma drainage and drain placement (1), a single suture securing the tip of the drain in the hematoma cavity (2), a combination purse-string and finger-trap knot to secure the drain near its exit site (3), and a folded (ie, butterfly) tape strip used to further secure the external drain to the adjacent cervical skin (4). B—Image obtained following activation of the vacuum reservoir for drainage. An Elizabethan collar was subsequently applied to the patient to protect the system from scratching and clawing. C—Image obtained immediately prior to drain removal (day 21). The ear's appearance was comparable to that of the unaffected right ear.

cutaneous tunnel between the 2 skin incisions. A hemostat was then introduced through the stab incision with its tip exiting the initial pinnal incision. A portion of the excess nonfenestrated portion of the drain was resected to facilitate drain passage. The free end of the drain was grasped and retracted out through the second stab incision.

The pinnal skin incision was closed with 2 or 3 simple interrupted 3-0 nylon skin sutures. The pinna was then gently manipulated to assure the drain was under no tension during normal movement of the pinna. A 2-0 nylon purse-string suture was then placed around the second cutaneous stab incision, and a finger-trap knot was used to secure the nonfenestrated portion of the drain exiting the skin. The remaining redundant

portion of the nonfenestrated external drain was shortened before connecting it to a vacuum reservoir[™] held at the estimated level of the ventral surface of a dog collar; this distance was selected to allow sufficient laxity in the drain tube to accommodate normal range of motion of the patient's head and neck. A short strip of surgical tape was applied perpendicularly to both sides of the drain, approximately 5 cm from the cutaneous exit site; an additional skin suture of 2-0 nylon was placed through the 2 tape tabs created on each side of the drain to minimize the risk of accidental drain displacement. Lastly, the activated vacuum reservoir was attached to the dog's collar to complete the procedure (Figures 2 and 3). During the procedure for dog 3, the convex surface of the pinna immediately took on a wrinkled appearance when the vacuum reservoir was activated, but this was not observed in the other patients.

All 5 patients recovered uneventfully after surgery and were discharged later the same day; tramadol[®] (2.0 mg/kg [0.91 mg/lb], PO, q 12 h) was prescribed for 3 days and amoxicillin-clavulanic acid[®] (13.75 mg/kg [6.25 mg/lb], PO, q 12 h) was prescribed for 7 days.

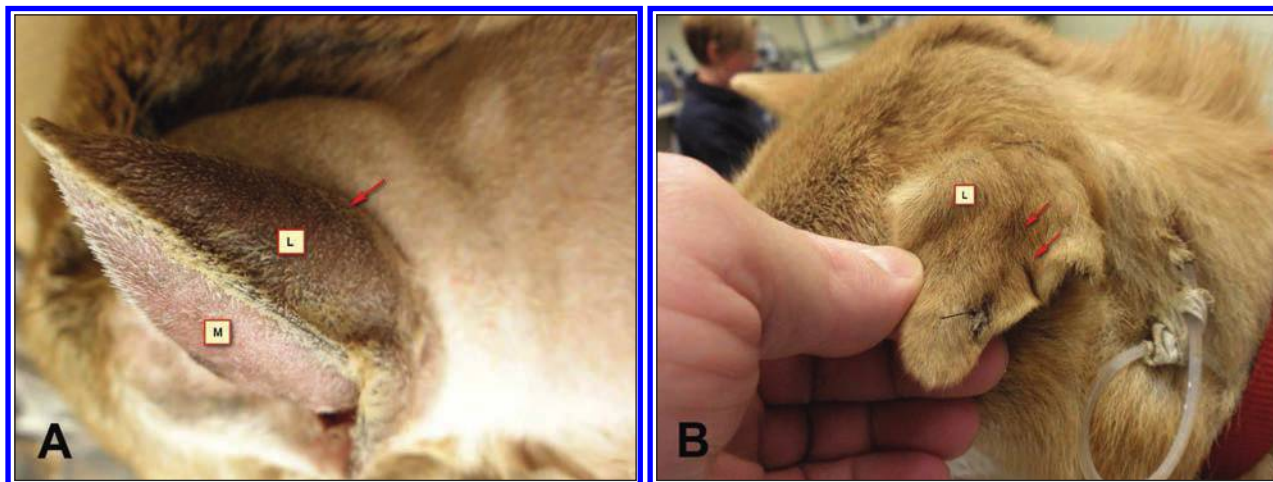


Figure 4—Photographs of a 10-year-old Shiba Inu with an aural hematoma of the left ear (dog 3). A—Caudal view of the pinna border, with the medial or concave (M) surface and lateral or convex (L) surface (arrow) silhouetting the disparity between the corresponding cartilaginous walls of the hematoma. Greater dilation or stretching of the lateral cartilaginous wall results in an offset realignment with the less elastic medial wall when the vacuum reservoir is activated. B—Image obtained immediately prior to drain removal (day 21). Notice the crinkled or wavy appearance of the lateral pinna surface (arrows).

An Elizabethan collar was placed on each dog to protect the drain and pinna from scratching. The owners were instructed on the use of the vacuum drain system; they recorded the daily volume of fluid retained in the reservoir. Each patient was rechecked on a weekly basis to assure the drain was functional and healing was progressing. The daily volume of fluid accumulated in reservoirs and removed by the owners was minimal, amounting to 1 to 2 mL/24 h for each patient. The drains and skin sutures were removed 18 days after surgery for dogs 4 and 5 and 21 days after surgery for dogs 1, 2, and 3 (Figures 3 and 4). All patients had follow-up examinations for ≥ 6 months after surgery.

All hematomas were completely resolved and surgical sites had healed normally ≤ 6 months after surgery. With the exception of dog 3, treated ears of all dogs were clinically normal as judged by visual and manual examination. On removal of the drain, the previously noted wrinkled appearance of the pinna persisted in this dog (Figure 4).

Although successfully used in 2 patients (dogs 2 and 3), the 10F fenestrated silicone drain with multiple circular perforations^j was problematic to extract: granulation tissue had entered a number of the perforations. Removal required moderate traction to stretch the drain, thereby releasing the drain perforations from the granulation plugs that formed within them. The subsequent use of cardiothoracic drain tubing with linear channel drainage^k resulted in effortless removal of the drains in dogs 4 and 5.

Discussion

Aural hematomas commonly develop in a variety of canine breeds. A major contributing cause of their formation is trauma, including head shaking secondary to otitis externa. A pinna also may strike a hard surface, contributing to vascular trauma.¹ Occasionally, dogs develop aural hematomas without a history of trauma or otitis externa. It had been previously proposed that aural hematomas have an immune-mediated basis,^{2,3} but this concept was challenged in a subsequent study.⁴

The rupture of the small vascular branches perforating the pinna cartilage (scapha)⁵ gives rise to aural hematoma formation. Shearing forces are likely created from head shaking or blunt trauma to the affected pinna, with a so-called stress riser effect occurring at the interface of the cartilage surface and blood vessels entering the scaphal foramina. Although hemorrhage has been described as occurring between the concave dermal surface of the pinnae and underlying perichondrium,^{1,6} other studies,^{7,8} in agreement with the author's clinical observations, have found that hematoma develops within the scaphal cartilage. The expanding blood and serum volume normally forms an elongated pocket parallel to the long axis of the pinna. As a result, the central scaphal cartilage partially separates or delaminates into medial and lateral walls surrounding the hematoma.

A variety of medical and surgical treatments have been described for the management of aural hematomas. Some authors have advocated intralesional and systemic corticosteroid treatment.^{2,3,9} Aspiration and use of compression bandages has been described with variable results.^{1,10,11} Surgical drainage has been advocated for those cases that fail to respond to these conservative medical approaches or as a primary method for resolving this condition. Drainage techniques involving the concave (medial) surface of the affected pinna include incisional drainage (linear or sigmoid incision) with a scalpel, usually supplemented with through-and-through sutures,^{1,10} fenestration of the concave pinna surface with a biopsy punch,^{1,12} passive drainage techniques including placement of fenestrated catheters or insertion of a teat infusion cannula,^{1,6,13–15} and an active (vacuum) drainage technique with a 3- to 5-mL evacuated glass tube and fenestrated butterfly catheter placed in the hematoma pocket via a stab incision.¹⁶ A bandage is normally required with these drainage techniques to protect the pinna and prevent drain displacement until the hematoma is resolved and healing is complete. Occasional plugging of the fenestrated butterfly catheter and the teat infusion cannula

with fibrin or blood clots has been noted by the author and other surgeons. Although the use of cyanoacrylate glue has been reported to close the hematoma pocket,¹⁷ the known inflammatory reaction of these compounds precludes their use.¹

Complications reported in treatment of aural hematomas include recurrent hematoma formation secondary to reinjury, insufficient drainage, or incomplete healing; permanent pinnal thickening and wrinkling or deformity of the ear secondary to fibrosis and contracture; obstruction or premature displacement of drainage tubes; delayed incisional healing; and problems related to application or maintenance of bandages to protect and immobilize the affected ear while providing local access to the drainage site. Securing a bandage can be particularly vexing, and the degree of difficulty varies according to pinna length, width, shape, and carriage (erect, dependent, and partially folded). It is common for veterinarians to periodically reinforce or replace the bandage on subsequent visits until healing is complete. Some dogs also may require consistent use of an Elizabethan collar to prevent repetitive pawing.^{1,3,4,6-16} Cumulatively, the costs associated with open wound care and periodic bandage changes can be expensive.

To the author's knowledge, reports to date describe access to aural hematomas from only the concave cutaneous surface of the pinna. With its relative paucity of hair and the intimate relationship of the skin with the underlying perichondrium, it provides veterinarians with the most easily visible direct access to the hematoma cavity. Draining hematomas from the convex (lateral) surface would be considered counterintuitive because of the relative separation of the overlying skin in relation to the perichondrium (with the exception of the apical third of the outer pinna). In the dogs of the present report, the minimally invasive placement of a vacuum drain into aural hematomas was easy to perform from the convex side of the pinna with 2 small incisions for drain placement. Moreover, the loose skin at the base of the pinna provided a protective location for securing the drain, without the need for a bandage with an Elizabethan collar in place.

The separation of the concave and convex aspects of the cartilage caused by hemorrhage accumulating in the scapha can result in symmetric swelling, with each surface equally stretched, or asymmetric deformation of the cartilage surfaces. Asymmetric deformity of the cartilaginous walls would explain the immediate pinnal folding noted on apposition in dog 3, whereas realignment of symmetric cartilage surfaces would result in the normal flat appearance of affected pinna in the remaining 4 patients after activation of the vacuum reservoir. In dog 3, the lateral cartilage wall of the hematoma was stretched to a greater degree than the medial wall affixed to the overlying dermal surface (Figure 4). With acute hematoma formation and subsequent drainage, cosmetic results would typically be expected to be superior to those following treatment of chronic hematomas with established fibrosis secondary to prolonged inflammation. Permanent thickening and pinnal deformity would be expected in patients with long-standing hematomas. Conventional incisional drainage of aural hematomas can also be expected to result in scarring

with pinnal deformation associated with collagen contraction (wound contracture).

During surgical preparation of the ear, the pinnal vessels can easily be identified, and the 1-cm access incision described in this report can be placed without inadvertent vascular injury. Careful blunt dissection of the subcutaneous pocket for drain placement further reduces the risk of vascular trauma. The pocket created at the base of the ear, adjacent to the exit incision, also provides a short-term subcutaneous pocket for any residual drainage to flow into after drainage tube removal.

Patients tolerated the drainage system well, and owners indicated that emptying the reservoir was simple to perform. Drainage was minimal, with volumes of approximately 1 to 2 mL reported on a daily basis. Use of an Elizabethan collar helped to assure that dogs could not traumatize the pinna or displace the drainage system. An 18- to 21-day time frame for drain and skin suture removal was selected on the basis of the early maturation phase of healing.

Silicone drain design proved important in management of aural hematomas in these patients. Although successfully used in 2 dogs, the 10F fenestrated silicone drain with multiple circular perforations was problematic to extract secondary to the ingrowth of granulation plugs. In dog 1, a 10-mm flat drain was used successfully, although it was marginally too wide for the hematoma in this patient, requiring the drain to be shortened to half the length of the hematoma. Effective drainage and ease of removal were obtained in 2 patients through the use of cardiothoracic drains that had 4 recessed linear channels for fluid removal (Figure 1). These drains are manufactured in a variety of diameters and thus may be the most useful for hematomas of various sizes.

This minimally invasive approach to aural hematomas resulted in minimal cutaneous scarring, which was concealed by subsequent hair growth. In the author's experience, incisional drainage with the adjunctive use of through-and-through mattress sutures is also highly effective in managing aural hematomas, but at a cost. Incisional drainage is more invasive, is more uncomfortable for the patient, and usually requires ≥ 3 weeks for the incision to heal completely. The degree of scarring can be substantial, and this can contribute to distortion (wrinkling) of the pinna. During incisional drainage, a stable bandage is required to protect the incision, and weekly bandage maintenance is required; an access window must be created in the bandage for the owner and veterinarian to clean and apply a protective dressing to the area on a daily basis until healing is complete. The risk of infection following incisional drainage, although low, would be expected to be greater than that associated with the small exit site of the vacuum drains used in dogs of this report. On the basis of these findings, this drainage technique is currently the preferred method of managing aural hematomas at the author's institution.

- a. Cefazolin, WG Critical Care, Paramus, NJ.
- b. Torbugesic, Fort Dodge Animal Health, Fort Dodge, Iowa.
- c. Novaplus, Hospira Inc, Lake Forest, Ill.
- d. Dexdomitor, Pfizer Animal Health, New York, NY.
- e. Propoflo, Abbott Laboratories, North Chicago, Ill.
- f. Isoflurane USP, Halocarbon Products Corp, River Edge, NJ.

- g. Lactated Ringer's injection USP, Baxter Healthcare Corp, Deerfield, Ill.
- h. Dermachlor, Butler Schein Animal Health, Dublin, Ohio.
- i. Flat drain, 10 mm, Tuzik, Boston, Mass.
- j. Round drain, 10F, Medline Industries Inc, Mundelein, Ill.
- k. Jackson-Pratt Hemaduct round drain, 15F, Cardinal Health, McGaw Park, Ill.
- l. Monosof, Covidien, Mansfield, Mass.
- m. Jackson-Pratt Reservoir, Cardinal Health, McGaw Park, Ill.
- n. Tramadol hydrochloride, Amneal, Hauppauge, NY.
- o. Clavamox, Pfizer Animal Health, New York, NY.

References

1. Lanz OI, Wood BC. Surgery of the ear and pinna. *Vet Clin North Am Small Anim Pract* 2004;34:567–599.
2. Kuwahara J. Canine and feline aural hematoma: clinical, experimental, and clinicopathologic observations. *Am J Vet Res* 1986;47:2300–2308.
3. Kurahara J. Canine and feline aural hematomas: results of treatment with corticosteroids. *J Am Anim Hosp Assoc* 1986;22:641–647.
4. Joyce JA, Day MJ. Immunopathogenesis of canine aural haematoma. *J Small Anim Pract* 1997;38:152–158.
5. Getty R, Foust HL, Presley ET, et al. Macroscopic anatomy of the ear of the dog. *Am J Vet Res* 1956;17:364–375.
6. Kolata RJ. A simple method for treating canine aural hematomas. *Canine Pract* 1984;11(3):47–50.
7. Dubielzig RR, Wilson JW, Seireg AA. Pathogenesis of canine aural hematomas. *J Am Vet Med Assoc* 1984;185:873–875.
8. Larsen S. Intrachondral rupture and haematoma formation of the external ear of dogs. *Pathol Vet* 1968;3:442–450.
9. Romatowski J. Nonsurgical treatment of aural hematomas (lett). *J Am Vet Med Assoc* 1994;204:1318.
10. Henderson RA. Reconstructive ear surgery. In: Swaim S, ed. *Surgery of traumatized skin*. Philadelphia: WB Saunders Co, 1980;70–77.
11. Bojrab MJ, Constantinescu GM. Sutureless technique repair of aural hematoma. In: Bojrab MJ, Ellison GW, Slocum B, eds. *Current techniques in small animal surgery*. 4th ed. Baltimore: Williams & Wilkins, 1889;97–98.
12. Dye TL, Teague HD, Ostwald DA, et al. Evaluation of a technique using the carbon dioxide laser for the treatment of aural hematomas. *J Am Anim Hosp Assoc* 2002;38:385–390.
13. Kagan KG. Treatment of canine aural hematoma with an indwelling drain. *J Am Vet Med Assoc* 1983;183:972–974.
14. Wilson JW. Treatment of auricular hematoma, using a teat tube. *J Am Vet Med Assoc* 1983;182:1081–1083.
15. Joyce JA. Treatment of canine aural haematoma using an indwelling drain and corticosteroids. *J Small Anim Pract* 1994;35:341–344.
16. Swaim SF, Bradley DM. Evaluation of closed-suction drainage for treating auricular hematomas. *J Am Anim Hosp Assoc* 1996;32:36–43.
17. Leftwich MW, Carey DP. Cyanoacrylate adhesive for aural hematoma. *Vet Med Small Anim Clin* 1981;76:1155.



From this month's AJVR

Medical infrared thermal imaging of cats with hyperthyroidism

Robert E. Waddell et al


Objective—To determine the usefulness of medical infrared thermal imaging (MITI) as a screening tool for hyperthyroidism in cats, evaluate the need for hair clipping over the ventral aspect of the neck to achieve optimal images, and determine whether there is a change in thermal patterns at 1 and 3 months after radioactive sodium iodide I 131 treatment.

Animals—17 cats with and 12 control cats without hyperthyroidism.

Procedures—All cats underwent MITI first with the hair present and then after the hair was clipped. Each cat with hyperthyroidism was subsequently appropriately treated SC with radioiodide; reevaluations, including MITI before and after hair clipping and measurement of serum thyroxine concentration, were performed 1 and 3 months after treatment.

Results—The MITI had 80.5% and 87.5% accuracy in differentiating hyperthyroid cats from clinically normal cats before and after the hair over the ventral aspect of the neck was clipped. Among cats with an initial serum thyroxine concentration > 4.0 µg/dL, the success rate for MITI-detected response to radioiodide treatment at the 1-month reevaluation was 92.86% in unshaved cats and 85.71% in shaved cats. The success rate for MITI-detected response to radioiodide treatment at the 3-month reevaluation was 100% in unshaved and shaved cats.

Conclusions and Clinical Relevance—Results indicated that MITI was successful in differentiating between hyperthyroid cats and clinically normal cats and identifying patients with thyroxine concentration within reference interval after radioactive sodium iodide I 131 treatment. (*Am J Vet Res* 2015;76:53–59)



See the midmonth issues
of JAVMA
for the expanded
table of contents
for the AJVR
or log on to
avmajournals.avma.org
for access
to all the abstracts.